

DIAGNOSTIC AND THERAPEUTIC INNOVATIONS
IN THE ERA OF PRECISION MEDICINE –
NUCLEAR MEDICINE MEETS NEURO-ONCOLOGY

ABSTRACTBOOK

NMN Symposium: Precision Medicine

09.-10. May 2025 /Vienna, Austria
Palais Ferstel

www.nmn-society.org

Nuclear Medicine and Neurooncology (NMN)

Only the conflict of interests of individuals with a disclosure are included in the respective abstracts.



Abstract Number: 3

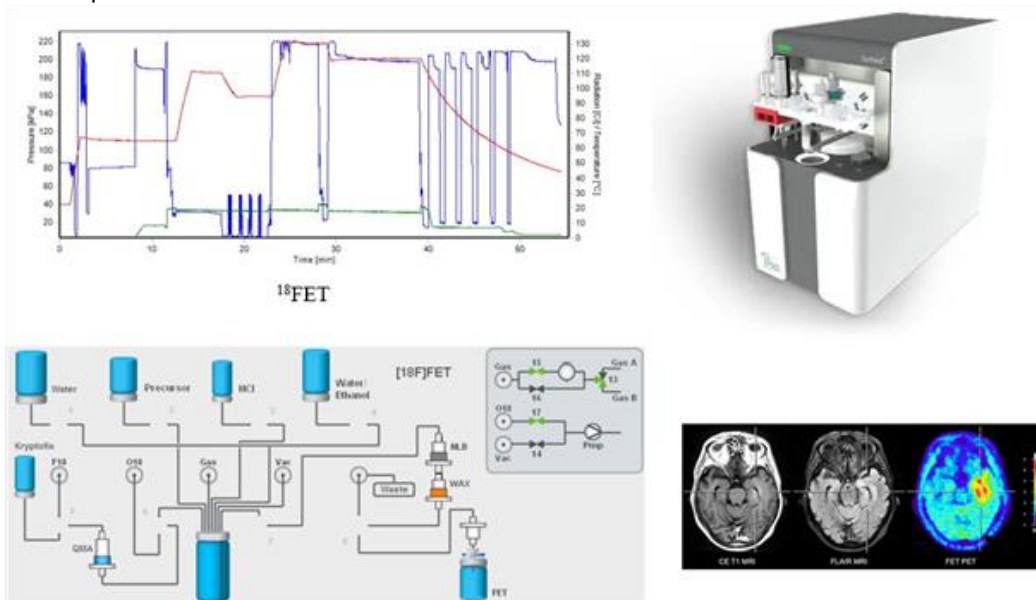
Abstract Title: Internal Production of FET Radiopharmaceutical for the Diagnosis of Brain Glioma Tumors

Authors:

Rahimi M¹, Hashemi Zadeh M¹, Khalili pour M¹

¹Pars Isotope Company, Rajaei shahr, Iran

The use of radiopharmaceuticals in diagnosing brain tumors, particularly gliomas, has gained significant attention due to their ability to provide valuable metabolic information. In this study, we describe the internal production of ¹⁸F-fluoroethyltyrosine (FET) using a synthesis module from IBA, focusing on the fluorination of ethyltyrosine, which was optimized for yield and purity. Radiochemical purity was assessed using high-performance liquid chromatography (HPLC), and stability was evaluated under various storage conditions, ensuring compliance with Good Manufacturing Practice (GMP) standards. The synthesized FET exhibited a radiochemical purity of over 95%, with high yield and consistent production across multiple batches. Stability tests revealed that FET remained stable for extended periods, maintaining its integrity under recommended storage conditions. Imaging studies using FET-PET in glioma-bearing animal models demonstrated a clear uptake in tumor regions, allowing effective visualization and assessment of tumor characteristics. These findings highlight the reliability and efficiency of our internal production process for FET, reducing dependence on external suppliers and enhancing the accessibility of this tracer in localized diagnostic capabilities for patients with gliomas. In conclusion, the internal production of FET radiopharmaceuticals represents a significant advancement in neuro-oncology diagnostics, providing a robust tool for glioma diagnosis, with future studies planned to assess clinical applicability across various glioma types and stages, further exploring its potential in personalized medicine.





Abstract Number: 4

Abstract Title: A Prospective Evaluation of Chemokine Receptor-4 (CXCR4) Overexpression in High-grade Glioma Using 68Ga-Pentixafor (Pars-Cixafor™) PET/CT Imaging

Authors:

Dadgar H¹

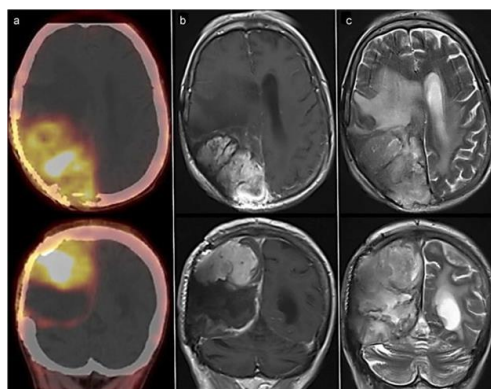
¹Cancer research Center, Imam Reza University, Nuclear Medicine and Molecular Imaging Research Center, Theranostics and PET, Mashhad, Iran

While MRI remains the gold standard for morphological imaging, its ability to differentiate between tumor tissue and treatment-induced changes on the cellular level is insufficient. GBM, demonstrate overexpression of chemokine receptor-4 (CXCR4). This study aims to evaluate the feasibility of 68Ga-Cixafor PET/CT as a tool to improve diagnostic accuracy in patients with high-grade glioma. Within 2 weeks of their MRI, these patients underwent 68Ga-Cixafor PET/CT scans to assess CXCR4 expression. Both visual scoring based on established criteria and semi-quantitative measures including SUVmax and TBR were calculated to analyze the PET/CT data.

Our retrospective study enrolled 29 histologically confirmed glioma patients with MRI findings consistent with high-grade gliomas. All patients underwent 68Ga-Cixafor PET/CT scans within 2 weeks of their MRI, specifically at one-hour post-injection time point. Visual assessment based on a standardized scoring system identified 27 positive scans out of 29 (93.1%). Median SUVmax was 2.31 (range: 0.49–9.96) and median TBR was 20 (range: 6.12–124.5). Pathological analysis revealed 5 grade III (17.24%) and 24 grade IV (82.75%) lesions among the 29 patients. Notably, the median SUVmax of grade IV lesions (2.85) was significantly higher than grade III lesions (1.27) ($P = 0.02$). Conversely, there was no significant difference in median TBR between grade IV (20) and grade III (22.37). These findings support the correlation between high CXCR4 expression, particularly in high-grade gliomas, and elevated uptake of 68Ga-Pentixafor. While areas with high uptake showed CXCR4 expression, areas with low uptake did not exhibit noticeable expression (data not shown).

Conclusion

This study demonstrated that 68Ga-Cixafor™ PET exhibits a TBR with minimal cortical uptake, significantly enhancing glioma detection compared to conventional imaging methods. This, combined with the potential therapeutic capabilities of CXCR4-targeting radiopharmaceuticals, highlights the promise of 68Ga-Cixafor as a valuable tool for not only improved glioma diagnosis but also personalized treatment strategies.





Abstract Number: 5

Abstract Title: Feasibility and initial experience of chemokine receptor-4 (CXCR4) expression using 68Ga-Pentixafor (Pars-Cixafor™) and O-2-18F-fluoroethyl-L-tyrosine (18F-FET) PET-MR image fusion in low- and high-grade gliomas

Authors:

Dadgar H¹

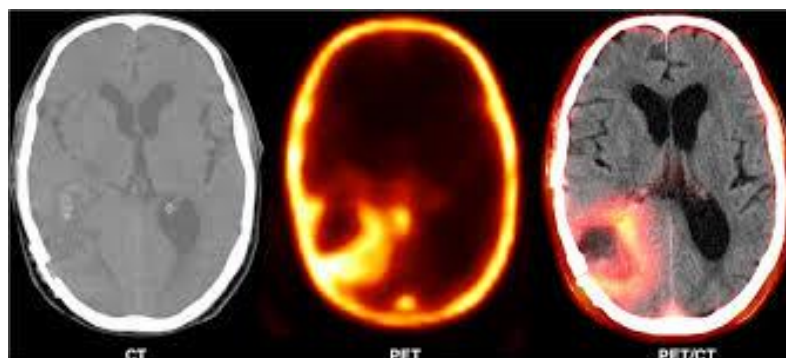
¹Nuclear Medicine and Molecular Imaging Research Center, Theranostics and PET, Iran

Amino acid agents and CXCR4 have been reported to be overexpressed in glioma cells, particularly in GBM. The current study aimed to evaluate the feasibility of 18F-FET, and 68Ga-Pentixafor PET/MR to increase diagnostic accuracy in low- and high-grade gliomas.

29 patients with recurrent glioblastoma underwent 68Ga-Pentixafor PET/CT before/after tumor resection. eleven patients with histopathologically proven brain tumor suspected of recurrent changes 3-4 months after surgery who were referred for an 18F-FET PET/CT scan. For both PET probes, visual and semi-quantitative calculation, including SUVmax and TBR, were performed.

Among 11 patients referred to 18F-FET PET/CT/MR imaging, nine cases (82%) had a positive MRI, six cases (55%) had a positive PET/CT and PET/MRI, and tumor recurrence was observed in 6 patients (55%). Follow-up indicated that accuracy, sensitivity, specificity, PPV, and NPV were 64%, 85%, 25%, 67%, 50% for MRI alone and 91%, 85%, 100%, 100% and 80% for PET/CT/MRI, respectively. Visual assessment of 68Ga-Pentixafor PET images revealed that 27/29 cases were positive, with a mean SUVmax of 3.92 (13 patients were female (13/29) and 16 patients were male (16/29); the mean age of the patients was 57.36 years). 17.24% (5/29) of patients had WHO grade III pathologies. Three out of twenty-nine participants had a stereotactic biopsy. The interval time between biopsy and imaging was 14-38 days. The mean SUVmax of WHO grade IV lesions was significantly higher than grade III (3.131 ± 3.01 vs. 1.99 ± 0.45) and the mean SUVmax of blood pool activity was reported as 1.277 in the superior sagittal sinus area. While the mean target-to-background ratio of grade IV patients was 29.45, all grade III gliomas showed lower lesion uptake than background activity considered in the contralateral cortex areas.

This study concluded that 68Ga-Pentixafor had a higher TBR than 18F-FET PET, with the ability to bond with ¹⁷⁷Lu-Pentixather.





Abstract Number: 6

Abstract Title: Prognostic stratification of newly diagnosed isocitrate dehydrogenase (IDH)-mutant gliomas by amino acid positron emission tomography (PET)

Authors:

Mair M^{1,2}, Werner J^{1,3}, Weller J⁴, Barci E², Katzendobler S⁴, Isakaj J², Aras T², Pühr H¹, Schabhuettl T^{1,2}, Kiesel B⁵, Widhalm G⁵, Woehrer A⁶, Nakuz T⁷, Hacker M⁷, Harter P^{8,9,10}, von Baumgarten L^{4,9,10}, Berghoff A¹, Thon N^{4,11}, Preusser M¹, Albert N^{2,9,10}

¹Division of Oncology, Department of Medicine I, Medical University of Vienna, Vienna, Austria, ²Department of Nuclear Medicine, LMU University Hospital, LMU Munich, Munich, Germany, ³Department of Neurology, Faculty of Medicine and University Hospital Cologne, University of Cologne, Cologne, Germany, ⁴Department of Neurosurgery, LMU University Hospital, LMU Munich, Munich, Germany, ⁵Department of Neurosurgery, Medical University of Vienna, Vienna, Austria, ⁶Division of Neuropathology and Neurochemistry, Department of Neurology, Medical University of Vienna, Vienna, Austria, ⁷Division of Nuclear Medicine, Department of Radiology and Image-guided Therapy, Medical University of Vienna, Vienna, Austria, ⁸Center of Neuropathology and Prion Research, Faculty of Medicine, LMU Munich, Munich, Germany, ⁹Bavarian Cancer Research Center (BZKF), Partner Site Munich, Munich, Germany, ¹⁰German Cancer Consortium (DKTK), Partner Site Munich, Munich, Germany, ¹¹Department of Neurosurgery, Knappschaft University Hospital Bochum, Bochum, Germany

Background

Prognostic stratification is of prime importance to guide treatment decisions in IDH-mutant glioma. Systematic data on the prognostic value of PET in molecular subgroups of glioma are scarce.

Methods

In this retrospective, bicentric study, patients with IDH-mutant glioma and amino acid PET ([¹⁸F]FET or [¹¹C]methionine) within one year before/after first surgery were included. PET imaging was evaluated following PET RANO 1.0 criteria, and uptake (maximum/mean tumor-to-background ratios; TBR_{max}/TBR_{mean}) as well as PET-positive volume (PET volume) were measured. Time to next intervention (TTNI) and overall survival (OS) were used as endpoints.

Results

In total, 457 patients were included (53.8% male; median age 40 years [range: 18-81]), of whom 251 (54.9%) had astrocytoma and 206 (45.1%) oligodendroglioma. In patients with astrocytoma undergoing PET before resection or before/after biopsy, TTNI was associated with TBR_{max} (HR 1.72 [95%CI: 1.32-2.24], p<0.001) and TBR_{mean} (HR 2.32 [95%CI: 1.45-3.70], p<0.001) independently from clinical variables such as age, WHO grade, MGMT promoter methylation, extent of resection and postoperative treatment. In patients with oligodendroglioma and PET before resection or before/after biopsy, PET volume (HR 1.16 [95%CI: 1.06-1.27], p<0.001) was independently associated with TTNI. Receiver operating characteristic (ROC) analysis for prediction of TTNI in astrocytoma revealed optimal TBR_{max} and TBR_{mean} thresholds of 1.98 and 1.92, respectively. For PET volume in oligodendroglioma, an optimal threshold of 43.15 ml was detected. In astrocytoma, univariate analysis showed an association of OS with TBR_{max} (HR 1.32 [95%CI: 1.07-1.62], p=0.010), TBR_{mean} (HR 1.73 [95%CI: 1.07-2.80, p=0.026), and PET volume (HR 1.20 [95%CI: 1.07-1.34]; p=0.002). TTNI analyses according to type of surgery (biopsy vs. resection) and timepoint of PET (before/after surgery) showed consistent results across subgroups.



NMN Symposium: Precision Medicine

09 - 10. May 2025 / Vienna, Austria

Palais Ferstel

Conclusions

In this cohort, PET parameters at diagnosis showed prognostic value in IDH-mutant gliomas. Prospective studies are needed to validate these findings and define prognostic models including PET imaging.

Author Disclosure: Mair M: research funding from Bristol-Myers Squibb and travel support from Pierre Fabre. Puhr H: has received travel support from Eli Lilly, MSD, Novartis, Pfizer and Roche and lecture honoraria from Eli Lilly. Woehrer A: has received honoraria for advisory board participation from Servier and Novocure. Widhalm G: has received honoraria for advisory board participation from Servier. Berghoff A: has received research support from Daiichi Sankyo and Roche and honoraria for lectures, consultation or advisory board participation from Roche, Bristol-Meyers Squibb, Merck, Daiichi Sankyo, AstraZeneca, CeCaVa, Seagen, Alexion, Servier as well as travel support from Roche, Amgen and AbbVie. Nakuz T: has received honoraria for lectures, consultation or advisory board participation from Servier and research funding from Novocure. Preusser M: has received honoraria for lectures, consultation or advisory board participation from Bayer, Bristol-Myers Squibb, Novartis, Gerson Lehrman Group (GLG), CMC Contrast, GlaxoSmithKline, Mundipharma, Roche, BMJ Journals, MedMedia, Astra Zeneca, AbbVie, Lilly, Medahead, Daiichi Sankyo, Sanofi, Merck Sharp & Dome, Tocagen, Adastr, Gan & Lee Pharmaceuticals, Janssen, Servier, Miltenyi, Böhringer-Ingelheim, Telix, Medscape, OnLive. Albert N: has received honoraria for lectures, consultation or advisory board participation from Novartis, Advanced Accelerator Applications, Telix Pharmaceuticals, OnLive, Medsir and Servier and research funding from Novocure and Telix Pharmaceuticals. All other authors declare no conflict of interest related to the present work.



Abstract Number: 7

Abstract Title: Preliminary theranostic candidates for Glioblastoma tumors based on Substance P derivatives.

Authors:

Mozaffari S¹, Abedi J¹, Khoshhosn H¹, Davarpanah M¹

¹Pars Isotope Co., Tehran, Iran

Background

Substance P (SP) is a neuropeptide with high-affinity to neurokinin 1 receptor (NK1R). It is involved in angiogenesis, mitosis and the progression of some tumors especially Glioblastoma multiforme (GBM) by overexpression of NK1Rs. The distribution density of NK1Rs correlates with the degree of malignancy. SP analogues could be developing radiopharmaceuticals for specific targeting of GBM via NK1Rs.

Methods

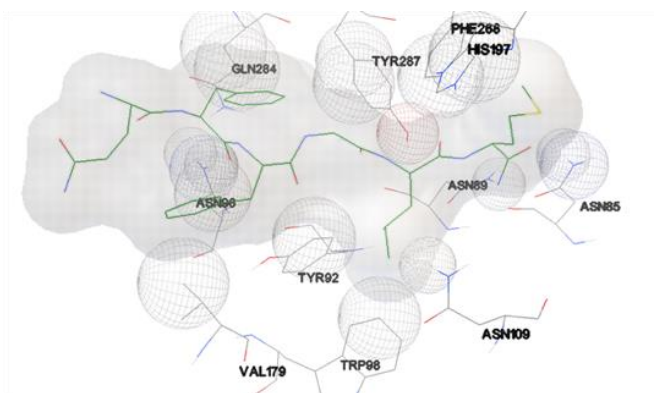
In our previous studies two derivatives of SP were synthesized and labeled with ^{99m}Tc and ¹³¹I radioisotope for theranostic application in GBM. The stability, protein binding and partition coefficient were examined. They evaluated by docking software and then the in vitro tests on human U373MG cell line and in vivo bio distribution studies on normal mice were done. After that some new small ligands were designed and evaluated by docking software and MD simulations. They are capable of radiolabeling with ⁶⁸Ga for PET and radiolabeling with ¹⁷⁷Lu, ²¹³Bi and ²²⁵Ac for Therapy.

Results

The proposed radioligands were interacted with crystal structure of NK1R acquired from PDB and displayed binding energies around -8 to -9 kcal/mol. The radiolabeled peptide showed an average radiochemical yield of 85%. Protein binding to human serum was 48 %. It was stable up to 24 h in saline and human serum. A value of -2.1 log P was calculated for radiolabeled peptide. Internalization study on U373MG cells showed a rapid binding to the cell membrane after 0.5 h and a slight increase in specific internalization during 4h. Saturation binding test concluded a mean K_d of 3.51 ± 0.89 nM. Biodistribution studies showed high accumulation in kidneys and salivary glands regions 1 h and 4 h post-injection of radiopeptide.

Conclusions

These derivatives could be theranostic candidates for GBM and other NK1R positive tumors. Design and further evaluations of new derivatives by ¹³¹I and ¹⁸F are ongoing.





Abstract Number: 8

Abstract Title: Efficacy and safety of ^{177}Lu -DOTATATE treatment in patient with neurofibromatosis type 2 and multiple intracranial meningiomas, after several courses of radiotherapy – a case report.

Authors:

Grzbiela H¹, Olczyk T²

¹III Radiotherapy and Chemotherapy Clinic, Maria Skłodowska-Curie National Research Institute of Oncology, Gliwice Branch, Gliwice, Poland, ²Department of Nuclear Medicine and Endocrine Oncology, Maria Skłodowska-Curie National Research Institute of Oncology, Gliwice Branch

Background

Neurofibromatosis type 2 is associated with several types of CNS tumors, including meningiomas, usually multiple and diagnosed at a young age. Surgery and radiotherapy are the most common treatment modalities, but, due to their somatostatin receptors expression, ^{177}Lu -DOTATATE may also be an option.

Material and Methods

We report the case of a male patient with neurofibromatosis type 2, 15 years old at the time of diagnosis, 24 years old at the time of ^{177}Lu -DOTATATE treatment. In 2011, he underwent neurosurgery for a cerebral convexity tumor (Atypical meningioma G2), in 2012 another neurosurgery for a parasagittal tumor (Atypical meningioma G2) and in 2019 the resection of a tumor adjacent to the frontal lobes (Transitional meningioma G1). He also underwent several courses of CyberKnife radiotherapy: in 2014 to the meningiomas adjacent to the medulla and of the cerebral falx; in 2015 to the meningiomas of the olfactory bulb and of the left sphenoid bone; in 2016 to the meningiomas of the left frontal and right parietal lobe. The MRI scan performed in June 2020 showed progression of the meningiomas of the left parietal lobe and the parasagittal meningioma, as well as radionecrosis. The tumors were ^{68}Ga -DOTATATE avid in PET scans.

Results

The patient received two infusions of ^{177}Lu -DOTATATE – in July and September 2020. The treatment was well tolerated, no toxicity was observed. Six months later, the MRI scan showed progression of the meningioma of the right parietal lobe, but the neurological status of the patient deteriorated significantly, so no further treatment was possible.

Conclusion

The ^{177}Lu -DOTATATE treatment of meningiomas is a valuable option and seems to be safe in patients who underwent several courses of radiotherapy. However, it must be taken into account that meningiomas in patients with neurofibromatosis type 2 are more aggressive and associated with early mortality.



Abstract Number: 9

Abstract Title: Is there a need for sex-sensitive [18F]FET PET evaluation? A retrospective study of sex-specific differences in [18F]FET uptake in glioma imaging

Authors:

von Polenz I¹, Mair M^{1,2}, Zounek A¹, Wiegand L¹, Barci E¹, Müller K^{1,3}, Harter P⁴, von Baumgarten L⁵, Thon N⁵, Kaiser L¹, Westphalen C⁶, Brendel M¹, Heinrich K⁶, Albert N¹

¹Department of Nuclear Medicine, LMU University Hospital, LMU Munich, , , ²University Clinic for Internal Medicine I, Department of Oncology, Medizinische Universität Wien, Vienna, , , ³Department of Neurology, LMU University Hospital, LMU Munich, , , ⁴Center for Neuropathology and Prion Research, LMU University Hospital, LMU Munich, , , ⁵Department of Neurosurgery, LMU University Hospital, LMU Munich, , , ⁶Department of Oncology and Hematology, LMU University Hospital, LMU Munich

Background

Preliminary studies indicate that female patients show higher [18F]FET uptake in the background than male patients in positron emission tomography (PET), which may have previously unexamined implications for lesion evaluation, target-to-background ratios (TBR) and PET-based tumor volume segmentation. We therefore investigated [18F]FET uptake in the healthy background and tumor, comparing female and male patients with glioma.

Methods

A cohort of patients with treatment-naive gliomas of WHO grade 2-4 was retrospectively analyzed. In addition to biological sex, characteristics such as age, body mass index (BMI) and use of cortisone or contraceptives at the time of imaging were recorded. PET analyses included the assessment of background uptake (SUVmeanBG) and target lesions (SUVmean, SUVmax, TBRmean, TBRmax) according to EANM/EANO/RANO/SNMMI guidelines using standardized crescent-shaped volumes of interest (VOI) in the contralateral hemisphere. Statistical models were used to investigate whether the measured values differ between male and female patients and whether additional parameters influence these values.

Results

After screening the entire cohort, over 240 patients met the inclusion criteria. Preliminary analyses of 86 patients (43 females and 43 males), adjusted for age, BMI and application dose, showed effects of sex ($p = 0.02$) on SUVmeanBG. The SUVmeanBG of the preliminary sample was calculated as $md = 0.98$ (IQR 0.26), with $md = 1.01$ (IQR = 0.28) for female patients and $md = 0.93$ (IQR = 0.23) for male patients. However, this effect wasn't found for tumoral uptake values. Full cohort results will be available at the time of abstract presentation.

Conclusion

Analysis of the preliminary cohort suggests sex differences in [18F]FET background uptake with significantly higher values in female patients. Although this did not result in significant differences in tumor-related parameters in this cohort, the influence of patient sex, particularly on the background activity-based tumor segmentation, should be analyzed in future quantitative PET studies.



Abstract Number: 10

Abstract Title: Somatostatin receptor–targeted radionuclide therapy for meningiomas: factors associated with therapeutic response and initial dosimetric data

Authors:

Boursier C¹, Zaragori T, Garabedian N¹, Imbert L¹, **Verger A¹**

¹CHRU Nancy, , France

Background

Somatostatin receptor–targeted radionuclide therapy (SSTR-RT) is currently used as an effective therapeutic option for refractory meningiomas. However, factors associated with response to this therapy as well as dosimetric data are scarce. This study aims to report on factors affecting therapeutic response in meningiomas treated with SSTR-RT and to collect initial dosimetric data.

Methods

Patients with refractory meningiomas, who underwent SSTR-RT with ¹⁷⁷Lu-DOTATATE from July 2021 to July 2024 and for whom dosimetric data were available, were retrospectively included. Clinical factors, WHO grading, previous therapy, 3D MRI volumes and pre-treatment PET uptake parameters were correlated with post-treatment progression as defined according to 3D RANO criteria. MRI growth rates, as well as dosimetric data obtained from 3 time points and with correction for partial volume effect, were also calculated.

Results.

Fifteen patients (61.9±10.5 years old, 7 women) underwent a median of 4 [2;4] cycles of ¹⁷⁷Lu-DOTATATE, with eight-week intervals between therapies, and with a median absorbed dose/cycle of 3.0 [2.1;4.8] Gy. High WHO grading, antecedent of bevacizumab therapy, and high SUV_{mean} meningioma uptake on pre-therapeutic PET were risk factors for post-treatment progression ($p \leq 0.05$). Growth rate measurements after therapy were significantly decreased in well-selected SSTR-RT candidates (i.e. patients presenting no risk factors) as compared to the other patients (9 vs. 6 patients, -111% vs. +125%, $p < 0.01$). In well-selected candidates, a significant correlation between absorbed dose/cycle and SUV_{mean} on the pre-therapeutic PET was observed ($r = 0.69$). However, no association between dosimetric data and growth rate measurements was observed.

Conclusion

SSTR-RT is effective in meningiomas having no risk factors for post-treatment progression, i.e. without factors of highly aggressive meningiomas. Absorbed doses in meningiomas treated by SSTR-RT are relatively low. In well-selected patients, a correlation between pre-therapeutic PET uptake and absorbed dose/cycle is observed, but no clinical dose-effect association is visualized.



Abstract Number: 11

Abstract Title: PET-based response assessment criteria for diffuse gliomas (PET RANO 1.0): methodological application in [18F]-FDOPA PET imaging

Authors:

Stien G¹, Zinsz A¹, Ahrari S¹, Taillandier L¹, Blonski M¹, Imbert L¹, Zaragori T¹, **Verger A¹**

¹CHRU Nancy, France

Background

The Response Assessment in Neuro-Oncology (RANO) group recently reported PET-based response assessment criteria for diffuse gliomas (PET RANO 1.0). The objective of this study was to evaluate the methodological application of these criteria for the amino acid [18F]-FDOPA radiotracer.

Methods

Patients with confirmed glioma who underwent at least one baseline [18F]-FDOPA PET scan were retrospectively included. The PET RANO 1.0 criteria were evaluated regarding their methodological application. Patients with at least one follow-up PET scan were evaluated with the PET RANO 1.0 criteria as compared to the routine interpretation of two experts not using the PET RANO 1.0 criteria, defined as the reference. The different PET parameters included in the PET RANO 1.0 criteria were evaluated separately regarding their contribution.

Results

Ninety patients (52.0±15.3 years old, 56% women) were included in this study regards to the methodology of application of the PET RANO 1.0 criteria, with 86% of patients presenting measurable diseases. Among these patients, 65 patients were evaluated for the comparison between the PET RANO 1.0 criteria and the expert interpretation: a concordance of 80%, equivalent for newly diagnosed and recurrent gliomas, as well as IDH-mutant vs. IDH-wildtype gliomas was found. The metabolic tumor volume represented the most contributive parameter (71% of cases) to the definition of response according to the PET RANO 1.0 criteria. Striatum infiltration, post-treatment related effects, measurable diseases criteria and thresholds for PET RANO 1.0 criteria were related to the cases discordances.

Conclusion

The PET RANO 1.0 criteria can be applied with [18F]-FDOPA imaging, with a reasonable concordance with results of an expert interpretation. Description of discordant cases should help to improve future PET RANO 1.0 criteria updating.



Abstract Number: 12

Abstract Title: ASSESSMENT OF QUALITY OF LIFE IN CANCER PATIENTS RECEIVING RADIOLIGAND THERAPY (RLT)

Authors:

Van Hemelrijck M¹, Albert N, Bultijnck R, Goffin K, Minniti G, Oyen W, Ramage J, Seront E, Silva J, van der Graaf W, van Herpen C, Deroose M C, Preusser M

¹King's College London, London, United Kingdom

Background

The European Organisation for Research and Treatment of Cancer (EORTC) Radioligand Therapy (RLT) Task Force (TF) was launched in June 2024 to enhance scientific and regulatory expertise, supporting impactful clinical trials. While RLT shows promise in improving quality of life (QoL) and survival, challenges persist, particularly regarding patient-reported outcomes (PROs) and health-related QoL (HRQoL). Existing EORTC QoL questionnaires for prostate and neuroendocrine tumours lack RLT-specific considerations, necessitating their integration into the EORTC QoL Group strategy.

Methods

As a TF, we aim to assess whether current EORTC QoL questionnaires adequately capture RLT-related concerns. If gaps are identified, we will determine whether to develop a standalone module or incorporate additional items into existing modules using the EORTC Item Library.

Our approach follows EORTC QoL Group guidelines and consists of two phases:

1. Identification of Relevant QoL Issues

A systematic literature review and interviews with patients and healthcare professionals will identify key QoL concerns for RLT patients. Using appropriate sampling matrices across languages, insights will be synthesised, rated for importance, and refined based on defined criteria.

2. Development of a Provisional RLT QoL Item List

Identified issues will be transformed into questionnaire items. Patients and healthcare professionals will review these for clarity and relevance, with feedback guiding final refinements. A decision will then be made on whether to develop a standalone module or integrate items into the Item Library.

Results

This initiative seeks to develop a validated, practical QoL assessment tool for RLT patients. Funding acquisition is ongoing, and collaboration opportunities remain open.

Conclusion

The EORTC aims to enhance survival and QoL by evaluating therapeutic strategies. With the rise of RLT for cancer, it is crucial to assess the EORTC QoL questionnaires' suitability and identify additional items to cover RLT-specific QoL aspects comprehensively.



Abstract Number: 13

Abstract Title: Fully automated evaluation of FET PET in brain tumor patients

Authors:

Ciantar K¹, Filss C^{1,2}, Stoffels G^{1,2}, Judov N¹, Hilgers J¹, Régio Brambilla C¹, Lerche C¹, Shah N^{1,3}, Mottaghy F^{2,4}, Langen K^{1,2}, Galldiks N^{1,5}, **Lohmann P^{1,2}**

¹Institute of Neuroscience and Medicine (INM-3/-4), Research Center Juelich, Juelich, Germany, ²Department of Nuclear Medicine, RWTH Aachen University Hospital, Aachen, Germany, ³Department of Neurology, RWTH Aachen University Hospital, Aachen, Germany, ⁴Department of Radiology and Nuclear Medicine, Maastricht University Medical Center (MUMC+), Maastricht, The Netherlands, ⁵Department of Neurology, Faculty of Medicine and University Hospital Cologne, University of Cologne, Cologne, Germany

Background

In addition to MRI, amino acid PET, particularly O-(2-[¹⁸F]fluoroethyl)-L-tyrosine (FET), has become an important imaging modality for brain tumor diagnostics. Further standardization is required to reduce variability in the assessment of quantitative FET PET parameters such as the maximum and mean tumor-to-brain ratios (TBR_{max}, TBR_{mean}) and metabolic tumor volume. To reduce the intra- and inter-reader variability in the assessment of quantitative FET PET parameters, we developed a fully automated workflow for the clinical evaluation of FET PET and compared its performance to human experts.

Material and Methods

We assessed 740 FET PET scans from 595 brain tumor patients (mainly glioma, 65%) at various disease stages performed on three different PET scanners across two institutions. The images were routinely evaluated by three experienced nuclear medicine physicians and re-analyzed using a fully automated workflow based on the previously developed Juelich Segmentation Tool for Brain Tumor PET (JuST_BrainPET). Parameters including the mean background standardized uptake value (background SUV_{mean}), TBR_{mean}, and TBR_{max} were computed and compared with expert evaluations using the Pearson correlation coefficients.

Results

The automated workflow correctly identified 526 FET-avid lesions with a sensitivity of 98% and an F1-score of 0.91. False positives were noted, but 74% of these were volumetrically smaller than 0.5 ml, i.e., considered non-measurable disease according to PET RANO 1.0. A strong correlation was observed between the automated and manual assessment, with correlation coefficients greater than 0.85 for all three metrics (Figure 1). Bland-Altman analysis showed a minimal bias of 1.1% towards overestimating the background SUV_{mean}, with a slight overestimation of TBR_{mean} (5.1%) and TBR_{max} (5.9%) (Figure 1). Scanner variations showed limited effects on the performance.

Conclusion

The presented fully automated workflow offers a fast and reliable evaluation of FET PET scans in patients with brain tumors, with a strong potential towards a better comparability and standardization.

Author Disclosure: Norbert Galldiks has received honoraria for lectures from Blue Earth Diagnostics, for advisory board participation from Telix Pharmaceuticals and Servier, and for consultancy services from Telix Pharmaceuticals. Philipp Lohmann has received honoraria for lectures from Blue Earth Diagnostics, and for advisory board participation from Servier. All other authors declare no competing financial interests.



NMN Symposium:
Precision Medicine

09 - 10. May 2025 / Vienna, Austria

Palais Ferstel

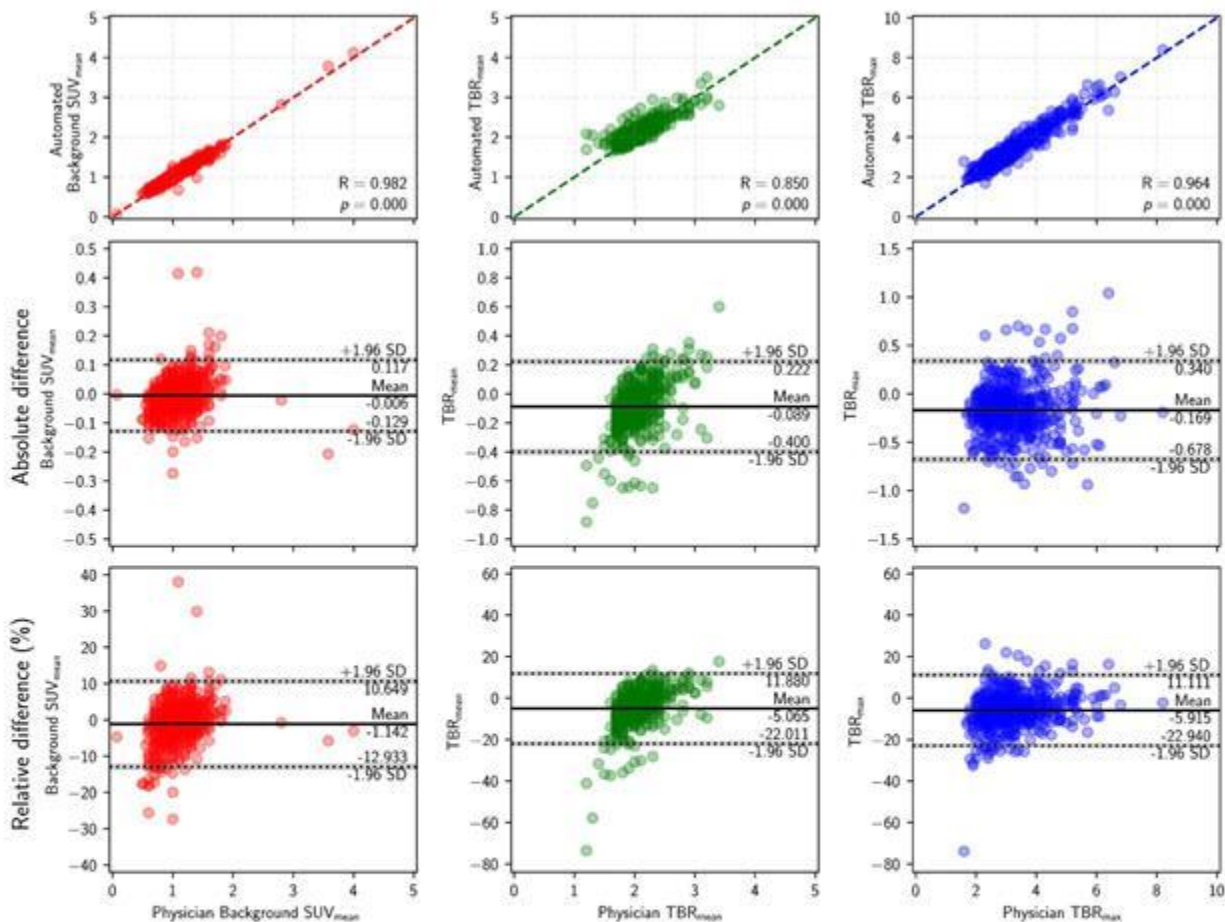


Figure 1: Pearson correlation coefficients and Bland-Altman analysis for the assessment of agreement in background SUV_{mean} (left), TBR_{mean} (center) and TBR_{max} (right) between physicians and the fully automated workflow. Dashed lines indicate equivalence between axes, solid lines show bias, and dotted lines show the 95% limits of agreement with grey shaded regions for the confidence intervals.



Abstract Number: 14

Abstract Title: [18F]Fluorethyltyrosine positron emission tomography for localisation of corticotroph pituitary adenomas in the initial evaluation of Cushing's disease

Authors:

Völter F¹, R. O. L. Schweizer J¹, Stüfchen I¹, Ritzel K¹, Zopp S¹, Werner R¹, Thorsteinsdottir J¹, Reincke M¹, Albert N¹

¹LMU, München

Background

The preoperative localisation of ACTH-producing pituitary adenomas remains challenging. MRI correctly visualizes up to 75% of ACTH-producing adenomas. In many patients, pituitary exploration has to be performed, with a risk of unnecessarily extensive resection, increasing the risk of postoperative pituitary insufficiency, or incomplete tumor removal. We therefore aimed to evaluate the potential of [18F]Fluorethyltyrosine positron emission tomography ([18F]FET PET/CT) in localising ACTH-producing pituitary adenomas in patients with first diagnosis of Cushing's disease.

Material/Methods

[18F]FET PET/CT was conducted in all patients with a primary diagnosis of Cushing's disease at LMU Hospital 06-12/2024. Dynamic PET images were acquired 0-40 min after injection with a mean injected dose of 173 MBq. Maximal tumor-to-background ratios (TBR_{max}) were determined comparing maximum standardized uptake values of pituitary adenomas to mean standardized uptake values of the right frontal and temporal lobe. Numeric values were reported with median (interquartile range).

Results

A total of 10 patients were included, 5 with microadenoma, 2 with macroadenoma, 3 with no visible lesion on MRI. The median preoperative ACTH level was 55.5 pg/mL (50.3-89.0), the median basal cortisol was 23.6 µg/dL (13.7-29.7). In all patients, dynamic [18F]FET PET/CT revealed a focal intrasellar hotspot indicating a pituitary adenoma (median TBR_{max} 3.2; 2.4-3.6). 6/10 patients underwent transsphenoidal surgery until 01/2025. In all operated patients, the focal intrasellar hotspot was consistent with the histopathologically proven corticotroph adenoma. 2 patients are still awaiting surgery, 1 patient refused surgery, 1 patient postponed surgery due to hospitalisation for severe depression. All operated patients showed a postoperative remission with a median basal ACTH of 6.0 pg/mL (4.5-20) and basal cortisol of 1.1 µg/dL (0.4-3.1). No patient experienced a postoperative anterior pituitary insufficiency.

Discussion/Conclusion

Functional imaging with [18F]FET PET/CT can be effective in localising ACTH-producing pituitary adenomas and can add valuable information to MRI and inferior petrosal sinus sampling.



Abstract Number: 15

Abstract Title: Paraneoplastic Syndromes and Autoimmune Encephalitis: Medical Records Review and FDG-PET/CT Outcomes

Authors:

Baldissin M^{1,3,4,5}, de Souza E^{4,5,7}, Watanabe N^{5,6}, Etchebehere E^{2,4}, Cendes F^{5,6}, Amorim B^{2,4}

¹Neurodiagnosis and Neurotherapy Clinic, Jundiaí, Brazil, ²Division of Nuclear Medicine, Department of Oncology and Radiology, University of Campinas (UNICAMP), Campinas, Brazil, ³Surgery Department, Jundiaí Medical School (FMJ), Jundiaí, Brazil, ⁴Cancer Theranostics Innovation Center (CancerThera), University of Campinas (UNICAMP), Campinas, Brazil, ⁵Brazilian Institute of Neuroscience and Neurotechnology (BRAINN), University of Campinas (UNICAMP), Campinas, Brazil, ⁶Department of Neurology, School of Medical Sciences, University of Campinas (UNICAMP), Campinas, Brazil, ⁷Nuclear Medicine Group, Biomedical Engineering Center, Nuclear Medicine Division, State University of Campinas (UNICAMP), Campinas, Brazil

Background

Paraneoplastic syndromes (PNS) are conditions oftentimes expressed as encephalitis. In about 60% of patients with autoimmune encephalitis (AE), highly specific antineuronal antibodies (e.g., Hu, Yo, NMDA) can be detected. In two-thirds of these patients, the neurological manifestation precedes the tumor diagnosis up to 4 years. The purpose of this study was to evaluate the clinical presentation and FDG-PET/CT findings in a group of patients clinically diagnosed with AE.

Materials and Methods

This study includes 37 patients, aged from 13 to 75 (47.08 ± 20,00 years), 65% female, who had been presented neurological manifestations of AE. Retrospectively, clinical records were analyzed by the neurology staff, being the clinical manifestations and the results of antibodies tests correlated with FDG-PET/CT brain images, analyzed by an expert in nuclear medicine.

Results

Among the patients studied, 24.3% had suspicion or confirmed neoplasia (most of them breast or thyroid lesions). Almost half of patients (49%) had positive antibodies. Some patients had negative antibodies (n = 12) and some were untested (n = 7). For most of the groups of patients, epilepsy was a common manifestation, followed by behavior and sensitive alterations. The exception is the aquaporin-4 antibody, for which muscular disorders are the main symptom, also highlighted in GAD patients. Considering the whole group, the areas of more common hypermetabolism are basal ganglia, temporal lobe, cingulate gyri, and precuneus. The main hypometabolic regions were the cerebellar hemispheres, and diffuse cortical areas (Fig.1).

Discussion

Patients with different neurological manifestations and antibodies may have different uptake patterns in brain FDG images. Independent of detection or suspicion of neoplasia, these findings can be a signal of PNS, contributing to the earlier diagnosis and definition of therapeutical approach.

Conclusion

Neurological manifestations and FDG-PET/CT findings showed specific signatures on the presence of symptoms of AE with or without PNS.



NMN Symposium:
Precision Medicine

09 - 10. May 2025 / Vienna, Austria
Palais Ferstel

Brain Regions	NM2A		Negative		EG1		YO		Hu		GAD		Amphiphysin		
	PRE	POS	PRE	POS	PRE	POS	PRE	POS	PRE	POS	PRE	POS	PRE	POS	
BG	Hyper	Border Hypo	Border Hypo	Border Hyper	Normal	Normal	Normal	Hypo	Hypo	Normal	Normal	Normal	Normal	Border Hyper	Normal
BG(L)	Hyper	Hypo	Hypo	Normal	Normal	Normal	Normal	Hypo	Hypo	Normal	Normal	Normal	Normal	Normal	Normal
BG(R)	Hyper	Normal	Normal	Hypo	Normal	Normal	Normal	Normal	Normal	Hypo	Normal	Normal	Normal	Hyper	Normal
C	Normal	Normal	Hypo	Border Hypo	Hyper	Hyper	Normal	Normal	Hypo	Hyper	Normal	Normal	Normal	Hypo	Normal
CI(L)	Border Hypo	Hypo	Hypo	Hyper	Hyper	Hyper	Normal	Normal	Hypo	Normal	Normal	Normal	Normal	Hypo	Hypo
CI(R)	Border Hypo	Hypo	Border Hypo	Normal	Hyper	Hyper	Normal	Normal	Hypo	Hyper	Normal	Border Hyper	Normal	Normal	Border Hyper
CE	Hypo	Hypo	Normal	Normal	Normal	Normal	Normal	Normal	Hypo	Normal	Normal	Normal	Hypo	Hypo	Hypo
CE(L)	Hypo	Hypo	Normal	Normal	Normal	Normal	Normal	Border Hypo	Normal	Normal	Normal	Border Hypo	Border Hypo	Border Hypo	Hypo
CE(R)	Hypo	Hypo	Normal	Normal	Normal	Normal	Normal	Normal	Hypo	Normal	Normal	Normal	Hypo	Hypo	Hypo
CI	Hypo	Border Hypo	Hypo	Hypo	Normal	Normal	Normal	Normal	Normal	Normal	Normal	Normal	Normal	Normal	Normal
CI(L)	Hypo	Border Hypo	Hypo	Border Hypo	Normal	Normal	Normal	Normal	Normal	Normal	Normal	Normal	Normal	Normal	Normal
CI(R)	Border Hypo	Normal	Hypo	Hypo	Normal	Normal	Normal	Normal	Normal	Normal	Normal	Normal	Normal	Normal	Normal
ST	Hyper	Border Hypo	Hypo	Hyper	Normal	Normal	Normal	Border Hypo	Hypo	Normal	Normal	Normal	Normal	Border Hyper	Normal
ST(L)	Hyper	Hypo	Hypo	Border Hyper	Normal	Normal	Normal	Hypo	Hypo	Border Hypo	Normal	Normal	Normal	Normal	Normal
ST(R)	Hyper	Normal	Normal	Hypo	Normal	Normal	Normal	Normal	Border Hypo	Normal	Normal	Normal	Hyper	Normal	Normal
F	Hypo	Hypo	Hypo	Hypo	Hypo	Hypo	Normal	Normal	Hypo	Hypo	Hypo	Hypo	Hypo	Hypo	Hypo
FR	Hypo	Hypo	Hypo	Hypo	Hypo	Normal	Normal	Normal	Hypo	Hypo	Hypo	Hypo	Hypo	Hypo	Hypo
FR(R)	Hypo	Hypo	Hypo	Hypo	Hypo	Hypo	Normal	Normal	Hypo	Hypo	Hypo	Hypo	Hypo	Normal	Normal
MT	Hyper	Normal	Border Hyper	Hyper	Normal	Normal	Normal	Hypo	Normal	Normal	Normal	Hyper	Hyper	Normal	Hypo
MT(L)	Normal	Normal	Normal	Hyper	Normal	Normal	Hypo	Hypo	Normal	Normal	Hyper	Border Hyper	Normal	Normal	Hypo
MT(R)	Hyper	Normal	Hyper	Hyper	Hypo	Hypo	Normal	Normal	Normal	Normal	Normal	Hyper	Normal	Normal	Normal
O	Hyper	Hyper	Normal	Hyper	Normal	Normal	Normal	Hyper	Hyper	Normal	Normal	Normal	Normal	Normal	Normal
O(L)	Hyper	Hyper	Normal	Hyper	Normal	Normal	Normal	Border Hyper	Border Hyper	Normal	Normal	Normal	Normal	Normal	Normal
O(R)	Hyper	Hyper	Border Hyper	Hyper	Normal	Normal	Normal	Hyper	Hyper	Normal	Normal	Normal	Normal	Normal	Normal
P	Hypo	Border Hypo	Hypo	Hypo	Normal	Normal	Normal	Normal	Hypo	Hyper	Hyper	Border Hypo	Hypo	Hypo	Hypo
P(L)	Hypo	Border Hypo	Hypo	Hypo	Normal	Normal	Normal	Normal	Hypo	Normal	Hypo	Hyper	Hypo	Hypo	Hypo
P(R)	Hypo	Hypo	Hypo	Hypo	Normal	Normal	Normal	Normal	Hypo	Hyper	Hypo	Normal	Normal	Normal	Normal
PR	Hypo	Normal	Hypo	Normal	Normal	Normal	Normal	Normal	Normal	Normal	Hypo	Normal	Normal	Normal	Normal
PR(L)	Hyper	Normal	Hypo	Normal	Normal	Normal	Normal	Normal	Normal	Normal	Border Hypo	Normal	Hypo	Hypo	
PR(R)	Border Hypo	Normal	Hypo	Normal	Normal	Normal	Normal	Normal	Normal	Normal	Normal	Normal	Hyper	Border Hyper	
T	Hyper	Border Hyper	Hypo	Normal	Normal	Normal	Hyper	Hyper	Normal	Normal	Normal	Normal	Hypo	Border Hypo	
TI(L)	Normal	Normal	Border Hypo	Hypo	Normal	Normal	Border Hyper	Normal	Normal	Normal	Normal	Normal	Hypo	Hypo	
TI(R)	Hyper	Normal	Normal	Normal	Normal	Normal	Border Hyper	Hyper	Normal	Normal	Normal	Normal	Normal	Normal	

Fig.1. Summary map highlighting the statistical differences of ¹⁸F-FDG uptake for different antibodies and brain regions, both in pre and posttreatment phases, as a descriptor of the neurological manifestations of the group of patients studied. BG: basal ganglia; C: central region; CE: cerebellum; CI: cingulate gyrus; ST: striatum; F: frontal lobe; MT: mesial temporal lobe; O: occipital lobe; P: parietal lobe; T: temporal lobe. L and R referred respectively to the left and right sides of the brain. Hyper: standard deviation of SUV mean > 2; Normal (yellow): -2.0 = standard of mean = 2.0. The borderline values refer to values around -2.0 (border hypo, light blue), and + 2.0 (border hyper, light red). (L) and (R) refer to left and right sides of brain.



Abstract Number: 16

Abstract Title: The Dural Tail in Meningiomas: Correlation of MRI, PET/CT, and neuropathological findings

Authors:

Greve T¹, Biczok A^{1,2}, Forbrig R³, Barci E⁴, Strübing F⁵, Harter P^{5,6,7}, Albert N^{4,6,7}, Schichor C¹, Ueberschaer M^{1,8}

¹Department of Neurosurgery, LMU University Hospital, LMU Munich, Munich, Germany, ²Department of Neurosurgery, Heidelberg University Hospital, Heidelberg, Germany, ³Department of Neuroradiology, LMU University Hospital, LMU Munich, Munich, Germany, ⁴Department of Nuclear Medicine, LMU University Hospital, LMU Munich, , Germany, ⁵Ludwig Maximilians University Munich, Medical Faculty, Center for Neuropathology and Prion Research, , Germany, ⁶German Cancer Consortium, Partner Site Munich, , Germany, ⁷Bavarian Cancer Research Center, Partner Site Munich, , Germany, ⁸Department of Neurosurgery, University Hospital Salzburg, Paracelsus Medical University, , Austria

Background

The dural tail sign of meningiomas on MRI is considered a tumor infiltration zone but may also reflect reactive changes. PET imaging with somatostatin receptor-based tracers has shown greater sensitivity than MRI in differentiating tumor tissue from tumor-free areas in meningiomas, but its predictive value at the dural tail remains unclear.

This interim analysis of the prospective dural tail study correlates MRI and PET/CT findings of the dural tail with histopathological data.

Methods

Patients >18 years with a newly diagnosed meningioma, MRI-detected dural tail and enhancement on SIFATATE-PET/CT, treated between 01/2023 and 12/2024, were screened. Biopsy sites were identified on pre-fused images: PET+MRI+, PET-MRI+, and PET-MRI-. Navigated intraoperative samples were taken (Figure 1). Histopathological findings were correlated with imaging. DNA-methylome analysis and Maas et al. risk stratification (MS) was performed.

Results

20 patients (15 female; mean age 59.9±10.8 years) were analyzed.

Histology showed two WHO grade 2 (MS 5 and 1) and 18 WHO grade 1 meningiomas (MS 2 in 4 patients, MS 0 in 8 patients, n/a in 6 patients).

In PET+MRT+, PET-MRT+ and PET-MRT- regions, 16/20 (80%), 9/20 (45%) and 3/20 (15%) specimens showed tumor cell infiltration, respectively.

No correlation was observed between presence of tumor cells in the dural tail specimens and WHO grade, MS or distance to the tumor margin.

MRI-positive dural tail showed a sensitivity (specificity) of 89.2% (50.5%).

PET-positive dural tail showed a sensitivity (specificity) of 57.1% (86.7%).

Congruent PET and MRI results (PET+MRT+ or PET-MRT-) had a sensitivity (specificity) of 84.2% (79.0%) and a PPV (NPV) of 77.8% (85.1%).

Conclusion

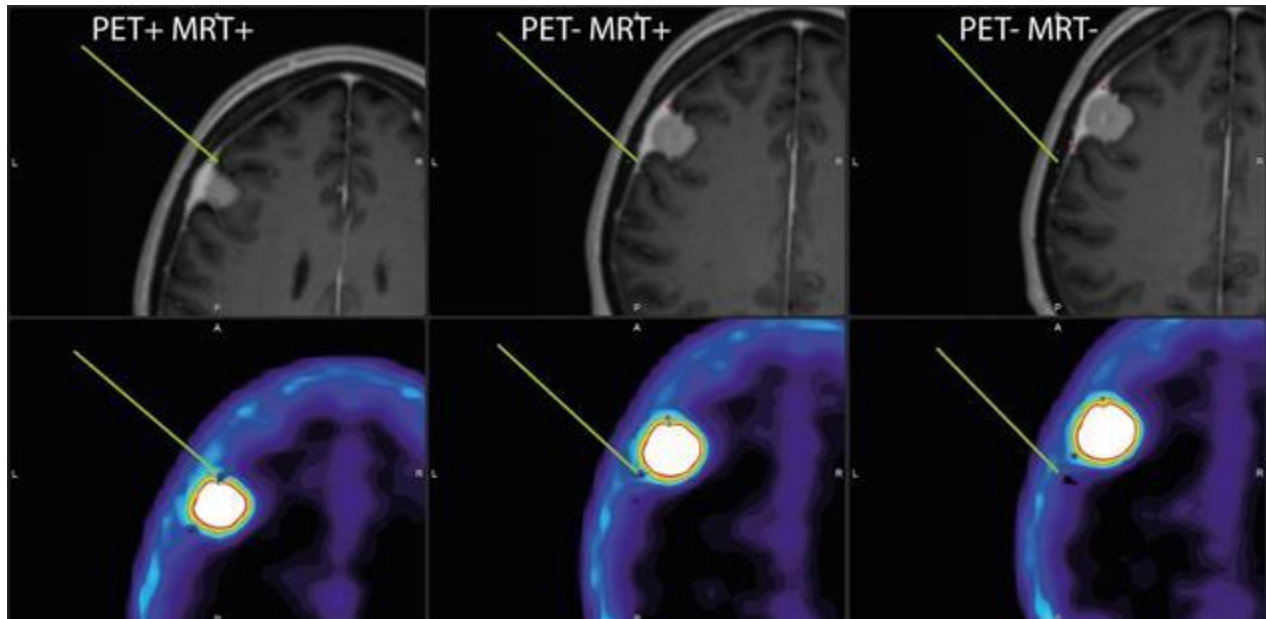
These preliminary results indicate that the combination of MRI and PET has a high predictive value in detecting tumor infiltration of the dural tail. The final results of the prospective trial are pending as the study still recruits.



**NMN Symposium:
Precision Medicine**

09 - 10. May 2025 / Vienna, Austria

Palais Ferstel





Abstract Number: 17

Abstract Title: Impact of preoperative somatostatin-receptor-targeted PET imaging on resection planning and surgical decision-making in meningiomas

Authors:

Teske N¹, Barci E², Mair M^{2,3}, Istrefi E², Biczok A⁴, Schichor C¹, Albert N^{2,5}, Greve T¹

¹Department Of Neurosurgery, LMU University Hospital, LMU Munich, Munich, Germany, ²Department of Nuclear Medicine, LMU Hospital, LMU Munich, Munich, Germany, ³Division of Oncology, Department of Medicine I, Medical University of Vienna, Vienna, Austria, ⁴Department of Neurosurgery, Heidelberg University Hospital, Ruprecht-Karls-University Heidelberg, Heidelberg, Germany, ⁵German Cancer Consortium, Partner Site Munich, Munich, Germany

Background

In meningiomas, preoperative MRI remains the primary imaging modality for resection planning, often complemented by CT imaging for skull base or intraosseous tumors. However, the advent of somatostatin-receptor (SSTR)-targeted PET promises significant advantages for delineating tumor boundaries. This study aims to investigate if inclusion of preoperative PET information to conventional MRI/CT influences resection planning in patients with meningioma.

Methods

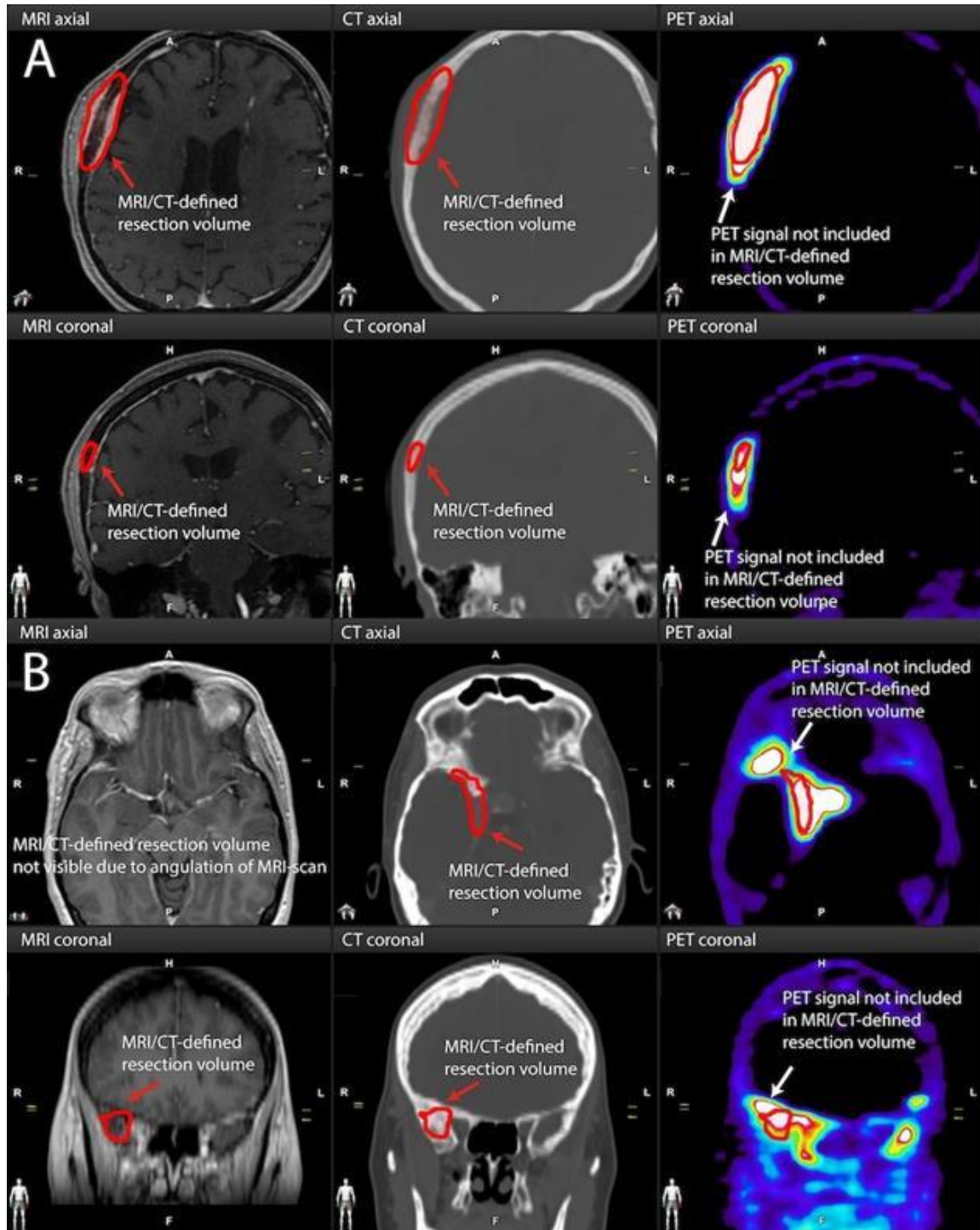
We retrospectively analyzed resection boundaries and parameters relevant for surgical planning including osseous resection in patients with meningioma who underwent preoperative PET imaging, based on suspicion of skull base and/or intraosseous involvement. Initially, the parameters were determined only on preoperative MRI/CT. Subsequently, resection planning was re-evaluated using the additional information provided by PET imaging. Imaging analyses were conducted using Brainlab Elements software.


Results

47 patients were included: 27 skull base, 11 convexity and 9 parafalcine meningiomas were identified. The extent of planned tumor resection was modified in most cases (31/47, 66.0%) after re-evaluating surgical planning with PET imaging. Planned tumor volumes were mainly altered in meningiomas located at the skull base (19/31, 61.3%), and in tumors with intraosseous involvement (26/31, 83.9%). In 26/31 patients (83.9%) planned tumor volume increased by 4.3 cm³, while it decreased in 5/31 cases (16.1%) by 1.6 cm³. Across all patients, median tumor volumes showed an increase after reviewing PET imaging of 0.15 cm³ (p = 0.001). PET imaging identified the need for further tumor resection to achieve complete resection in 9/47 patients (19,1%), who were initially considered completely resectable using MRI/CT-based planning.

Conclusion

Our study shows that preoperative PET imaging may significantly extend resection boundaries in meningiomas. Our data highlights the potential limitation of MRI/CT-based planning alone, which may result in an incomplete resection plan. These findings suggest that PET imaging serves as a promising preoperative tool that could enhance surgical precision in meningioma surgery.





Abstract Number: 18

Abstract Title: Targeting fibroblast activation protein in brain metastases: development and evaluation of a novel alpha-ketoamide-based FAP radioligand

Authors:

Vymola P¹, Simkova A², Vetrik M³, Sidej N², Dusa M¹, Kucka J³, Ksandrova E¹, Ormsby T², Trajhan F², Konvalinka J², Hruby M³, Sacha P², Sedo A¹, Busek P¹

¹First faculty of medicine, Charles University, Prague, Czech Republic, ²Institute of Organic Chemistry and Biochemistry of the Czech Academy of Sciences, Prague, Czech Republic, ³Institute of Macromolecular Chemistry, Czech Academy of Sciences, Prague, Czech Republic

Background

Brain metastases are the most common malignant tumors of the central nervous system in adults, affecting approximately 20% of patients with solid cancers. Current therapeutic options remain limited. We have recently demonstrated that fibroblast activation protein (FAP) is expressed in brain metastases, making it a promising target for theranostic applications. Here we aimed to develop and test novel FAP-targeting radioligands based on alpha-ketoamide FAP inhibitors (FAPi) in vitro and in vivo models.

Material and methods

Novel alpha-ketoamide FAPi with variable linker lengths were radiolabeled with ^{99m}Tc and their binding and internalization was assessed in vitro. Biodistribution studies were conducted in mice bearing FAP-expressing subcutaneous tumors and intratumoral accumulation was visualized using SPECT imaging. The most promising candidate was further tested in an intracranial tumor model.

Results

Among the tested compounds, ^{99m}Tc-labelled NS654 demonstrated specific binding to FAP-expressing cells and efficient internalization in vitro. In vivo, it exhibited favorable pharmacokinetics, with selective accumulation in FAP-expressing subcutaneous tumors. Notably, the compound was able to cross the blood-tumor barrier and accumulate in intracranial tumors.

Conclusion

We developed a novel ^{99m}Tc-labeled FAP radioligand using an alpha ketoamide inhibitor. Its favorable in vivo properties, including penetration of the blood-tumor barrier, highlights its potential for imaging brain metastases. These findings support further development of alpha-ketoamide-based FAP-targeting radioligands for theranostic applications.

Funding

Supported by the project National Institute for Cancer Research (Programme EXCELES, LX22NPO5102) by the EU, Ministry of Health of the Czech Republic and NU22-03-00318.



Abstract Number: 19

Abstract Title: Metabolic and Molecular PET Profiling of Glioblastoma and Metastatic Brain Tumors: Key Markers for Differentiation

Authors:

Miyake K¹, Tatano M¹, Kanda T¹, Suzuki K¹, Fujimori T¹, Ogawa D¹, Hatakeyama T¹, Okauchi M¹, Kawanishi M¹

¹Department Of Neurological Surgery, Kagawa University Faculty Of Medicine, Kagawa, Japan, Kagawa, Japan

Background

Diagnosing brain tumors solely with MRI is challenging. This study evaluates the utility of multiple PET tracers—FDG (glucose metabolism), MET (amino acid metabolism), FLT (vascular permeability), FMISO (hypoxic regions), and THK5351 (tau protein and MAO-B expression)—in differentiating glioblastoma (GBM) from metastatic brain tumors (Meta).

Material and Methods

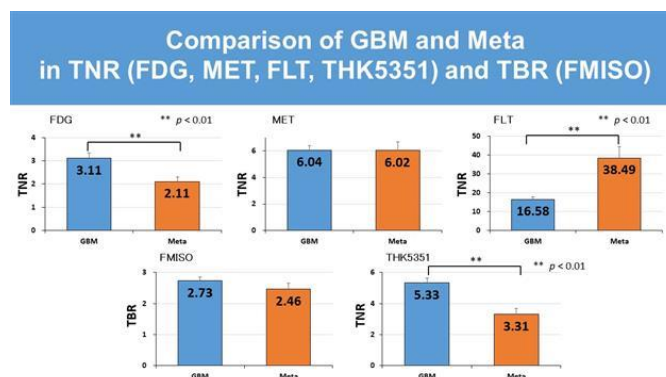
We analyzed 66 GBM and 22 Meta cases (10 lung, 3 breast, 2 colon, 1 hepatic, 1 renal, 1 bladder, 1 leiomyosarcoma, 1 testicular, 1 ovarian, 1 unknown primary) that underwent PET imaging (FDG, MET, FLT, FMISO, THK5351) in our department between April 2020 and December 2024. The tumor lesion-to-normal tissue ratio (TNR) and tumor lesion-to-blood ratio (TBR) were calculated. Metabolic tumor volume (MTV), defined as the tumor volume with a standardized uptake value (SUV) exceeding 42% of SUV_{max}, was measured for each PET scan. MTV/FLAIR and MTV/T1-weighted imaging with gadolinium enhancement (T1Gd) volume ratios were compared.

Results

For TNR and TBR, GBM exhibited significantly higher values for FDG (3.1 vs. 2.1, $p=0.001$) and THK5351 (5.3 vs. 3.3, $p=0.0002$), whereas FLT was significantly higher in Meta (16.6 vs. 38.5, $p=0.003$). In MTV/FLAIR volume, GBM demonstrated significantly higher values across all PET tracers: FDG (0.3 vs. 0.2, $p=0.03$), MET (0.6 vs. 0.3, $p<0.001$), FLT (0.5 vs. 0.2, $p=0.004$), FMISO (0.3 vs. 0.2, $p=0.002$), and THK5351 (0.9 vs. 0.3, $p<0.001$). In MTV/T1Gd volume, GBM showed significantly higher values for MET (3.4 vs. 1.3, $p=0.04$) and FMISO (1.6 vs. 1.0, $p=0.03$).

Conclusion

GBM exhibited higher MET and FMISO MTV/T1Gd volumes than Meta, while FLT was higher in Meta and THK5351 was higher in GBM for TNR. These PET-based markers may serve as valuable tools for distinguishing GBM from Meta.





Abstract Number: 20

Abstract Title: Multi-site, prospective trial evaluating FET-PET In Glioblastoma (FIG) Study (TROG 18.06): Trial in progress - central nuclear medicine and radiation oncology review of FET-PET biologic target volume delineation for radiotherapy planning

Authors:

Koh E^{1,2}, Francis R^{3,4}, Lee S^{5,6}, Lau E^{6,7}, Thomas E³, Gan H^{5,7}, Whitehead A⁸, Moore A⁸, Dykyj R⁸, Cook O⁸, Rossi A⁸, Barry N^{9,10}, Ebert M^{9,11}, Ng S¹², Pinkham M^{13,14}, Back M^{15,16}, Bucknell N¹¹, Evans H⁸, Bailey D^{16,17}, Moffat B^{18,19}, Fitt G^{19,20}, Scott A^{5,6}

¹Liverpool Hospital, South Western Sydney Local Health District, Sydney, Australia, ²South Western Sydney Clinical School, Faculty of Medicine, University of New South Wales, Sydney, Australia, ³Department of Nuclear Medicine, Sir Charles Gairdner Hospital, Nedlands, Australia, ⁴Medical School, The University of Western Australia, Crawley, Australia, ⁵Tumour Targeting Program, Olivia Newton-John Cancer Research Institute, Heidelberg, Australia, ⁶Department of Molecular Imaging and Therapy, Austin Health, Heidelberg, Australia, ⁷Austin Health, Department of Medical Oncology, Melbourne, Australia, ⁸TROG Cancer Research, Newcastle, Australia, ⁹School of Physics, Mathematics and Computing, University of Western Australia, Crawley, Australia, ¹⁰Centre for Advanced Technologies in Cancer Research (CATCR), Perth, Australia, ¹¹Department of Radiation Oncology, Sir Charles Gairdner Hospital, Perth, Australia, ¹²Austin Health, Department of Radiation Oncology, Melbourne, Australia, ¹³Department of Radiation Oncology, Princess Alexandra Hospital, Brisbane, Australia, ¹⁴Icon Cancer Centre North Lakes and Greenslopes Private Hospital, Brisbane, Australia, ¹⁵Department of Radiation Oncology, Royal North Shore Hospital, St Leonards, Australia, ¹⁶Faculty of Medicine & Health, University of Sydney, Sydney, Australia, ¹⁷Department of Nuclear Medicine, Royal North Shore Hospital, St Leonards, Australia, ¹⁸Melbourne Brain Centre Imaging Unit, University of Melbourne, Melbourne, Australia, ¹⁹Department of Radiology, University of Melbourne, Melbourne, Australia, ²⁰Department of Radiology, Austin Health, Heidelberg, Australia

Background

To provide 1) a 'trials in progress' update from the multi-site prospective Australian trial evaluating O-(2-[18F]-fluoroethyl)-L-tyrosine Positron Emission Tomography (FET-PET) in Glioblastoma (FIG) study and 2) assess impact of both central Nuclear Medicine Physician (NMP) and Radiation Oncology (RO) review of FET-PET1 delineation of biological target volume (BTV) for radiotherapy (RT).

Material and Methods

Adult GBM participants across 11 Australian sites undergo FET-PET post-surgery/pre-chemo-RT [CRT] (FET-PET1), one month post CRT (FET-PET2) and at suspected clinical and/or MRI progression (FET-PET3). Group 1 participants enter at timepoint 1 (FET-PET1 with MRI1), whilst Group 2 enter at timepoint 2. Adjuvant RT target volumes are derived per contrast MRI with hybrid post-hoc RT volumes incorporating FET-PET1 NMP-derived BTV utilising MiM version 7.0.

Results

Since recruitment commenced in January 2021, 229 (n=155 Group 1 and n=74 Group 2) participants have been enrolled, with Group 1 target recruitment now achieved. During trial credentialling, results demonstrated deviations in FET-PET1-derived BTV in 25/72 (34.7%):13 minor and 12 major. Central NMP of 121/143 prospective participant FET-PET1 cases across 11 sites has demonstrated 18/121 (14.9%) required resubmission. Reasons for resubmission/protocol deviation included Static GTV over-contouring (n=12), incorrect imaging sequence selection within MiM workflow (n=3), static FET interpretation issues (n=2) and



Nuclear Medicine and Neurooncology (NMN)

NMN Symposium: Precision Medicine

09 - 10. May 2025 / Vienna, Austria

Palais Ferstel

dynamic volume of interest change in size/position during workflow (n=1). Central RO review and comparison of standard versus hybrid BTV is progressing.

Discussion / Conclusion

Improvements in resubmission rates from credentialing to prospective phases have been seen, however both central NMP and RO review of FET-PET1-derived BTV delineation remain crucial. FIG trial recruitment will continue until the full evaluable cohort to assess the pseudoprogession outcome is achieved. The FIG study is the largest prospective multi-site study of its kind addressing 1) FET-PET's impact on adjuvant radiation planning and 2) its role in management of pseudoprogession and prognostication.



Abstract Number: 21

Abstract Title: Accelerate.eu: Astatine-211 Theranostic European Initiative

Authors:

Levillain H¹, Cristiana Gameiro-Paris C, Harray J, Royer Moes A, Gebhart G, Abrunhosa A, Flamen P

¹Institut Jules Bordet - Hopital Universitaire De Bruxelles, Brussels, Belgium

Introduction

Accelerate.EU brings together 17 European partners to develop novel radiotheranostic pairs using the alpha emitter astatine-211 (²¹¹At) for therapy, paired with companion diagnostics radiolabeled with fluorine-18 (¹⁸F) or iodine-123 (¹²³I) for PET and SPECT imaging. The project targets pancreatic, brain, and breast cancers, with a key focus on developing a cost-effective cyclotron for reliable ²¹¹At production to support clinical applications.

Method

Accelerate.EU integrates the entire ²¹¹At value chain, from production to early clinical studies, ensuring just-in-time availability. The preclinical and clinical pipeline targets fibroblast activation protein (FAP) for triple-negative breast cancer and neurotensin receptor 1 (NTR1) for pancreatic ductal adenocarcinoma. A major focus is the neurokinin-1 receptor (NK1R), part of the tachykinin receptor subfamily of GPCRs, where ²¹¹At-labeled substance P will be explored for locoregional glioblastoma treatment.

Results

The project will establish a dedicated hub for ²¹¹At-based radiotheranostics, enhancing patient selection for targeted alpha therapy (TAT) and improving quality of life and survival. Preclinical data on ¹²³I-FAPi, ²¹¹At-FAPi/NTR1i, and ²¹¹At-FAPi/Sub P will support clinical trials, alongside radiobiological characterization of ²¹¹At-FAPi. Initial safety and efficacy of ²¹¹At-FAPi/Sub P, as well as the imaging performance of ¹²³I-FAPi, will be clinically validated.

Conclusion

Accelerate.EU is a transformative initiative advancing ²¹¹At-based radiotheranostics for aggressive cancers. By developing cost-effective cyclotrons and a stable ²¹¹At supply chain, the project strengthens Europe's leadership in nuclear medicine and addresses future global demand.



Abstract Number: 22

Abstract Title: Approaches to enhance the delivery of EGFR-affibody based agents for radionuclide therapy with terbium-161

Authors:

Dar D¹, Rivens I¹, Da Pieve C¹, Ter Haar G¹, Harris E¹, Kramer-Marek G¹

¹The Institute of Cancer Research, 15 Cotswold Road, United Kingdom

Background

Glioblastoma is an aggressive malignancy with limited treatments. Targeted radionuclide therapy (TRT) delivers ionising radiation to tumours via radiolabelled molecules targeting specific antigens. As EGFR is overexpressed in GBMs, we evaluated the efficacy of 161Tb-labelled EGFR-targeting affibody molecule (ZEGFR:03115) in subcutaneous U87-MGvIII tumours.

PET imaging was used to assess whether focused ultrasound (FUS) with microbubbles (MB), known to transiently open the blood-brain barrier, enhances the delivery of 89Zr-DFO-ZEGFR:03115 to orthotopic U87-MGvIII tumours. Ultimately, this approach aims to facilitate 161Tb-DOTA-ZEGFR:03115 delivery to brain tumours, improving therapeutic efficacy.

Methods

Western blot was performed to confirm EGFR expression. 161Tb-DOTA-ZEGFR:03115 binding specificity was evaluated in vitro using U87-MGvIII(EGFR+) and GL261(EGFR-) cells. Subcutaneous U87-MGvIII tumour-bearing mice received intratumoural injections of 2, 10, or 20 MBq 161Tb-DOTA-ZEGFR:03115 and tumour volumes were monitored for up to 120 h post-injection. Organ biodistribution was analysed at 24, 48, and 120 h. Immunohistochemistry was performed to evaluate proliferation and DNA damage. For orthotopic tumours, mice underwent FUS+MB treatment while receiving an intravenous ⁸⁹Zr-DFO-ZEGFR:03115 injection. PET imaging and biodistribution were conducted at 3 and 24 h post-injection.

Results

Cell-associated 161Tb-DOTA-ZEGFR:03115 radioactivity corresponded with EGFR expression, and pre-incubation with ZEGFR:03115 blocked 161Tb-DOTA-ZEGFR:03115 binding. Subcutaneous U87-MGvIII tumour growth was delayed in an activity-dependent manner, with 20 MBq stabilising tumour growth compared to the control group. Biodistribution analysis showed high 161Tb-DOTA-ZEGFR:03115 tumour retention with low uptake in healthy tissues. Kidney accumulation demonstrated renal clearance. Ex vivo staining showed reduced Ki67 expression and increased γ H2AX phosphorylation. PET imaging demonstrated increased uptake of systemically delivered 89Zr-DFO-ZEGFR:03115 in orthotopic tumours exposed to FUS+MB, compared to non-exposed tumours.

Conclusion

Intratumoural 161Tb-DOTA-ZEGFR:03115 delivery inhibited tumour growth and exhibited a visual increase in H2A.X phosphorylation, demonstrating early efficacy. FUS+MB enhanced 89Zr-DFO-ZEGFR:03115 delivery in orthotopic tumours, and ongoing studies are evaluating combinatorial delivery approaches to improve 161Tb-DOTA-ZEGFR:03115 therapeutic outcomes.

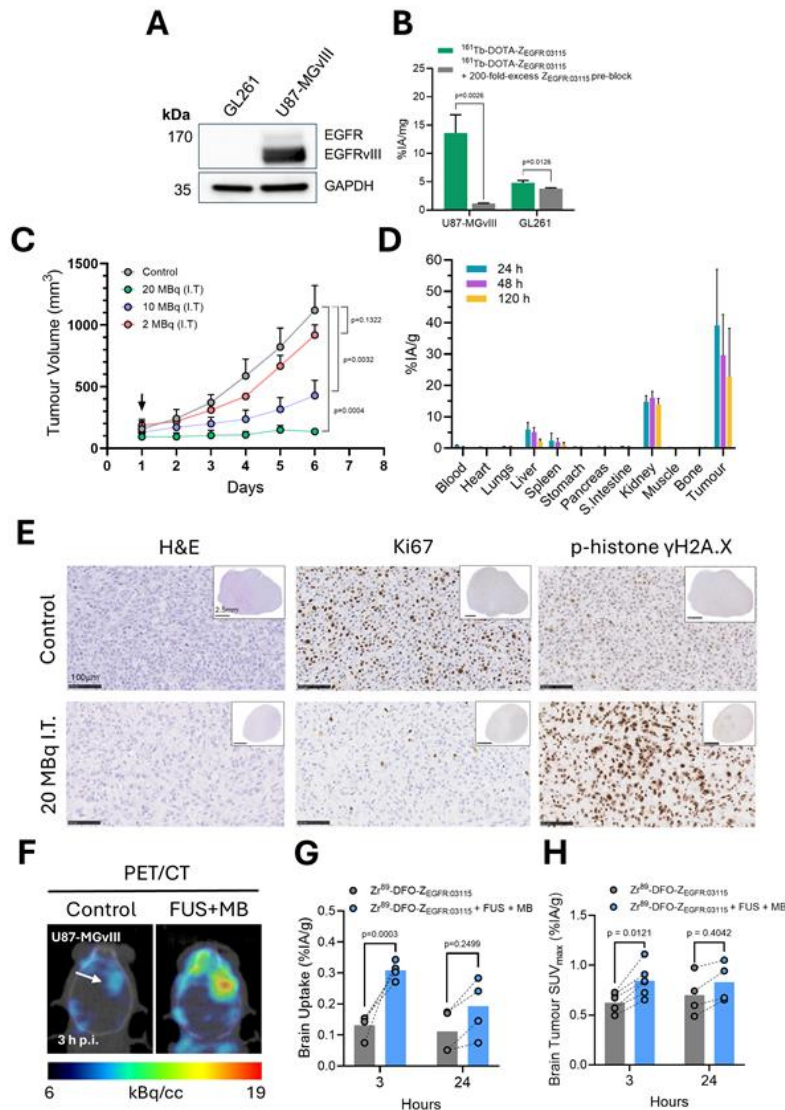


Figure 1. $^{161}\text{Tb-DOTA-Z}_{\text{EGFR-03115}}$ therapy in subcutaneous U87-MGvIII tumours and FUS+MB enhanced $^{89}\text{Zr-DFO-Z}_{\text{EGFR-03115}}$ delivery in orthotopic U87-MGvIII tumours. **A)** Western blot showing EGFR expression in GL261 and U87-MGvIII cells **B)** Specificity binding assay using $^{161}\text{Tb-DOTA-Z}_{\text{EGFR-03115}}$ (10 nM) alone or with a 10-minute pre-incubation with $\text{Z}_{\text{EGFR-03115}}$ (2 μM). Data is presented as the % of injected activity normalised to protein concentration. The unpaired t test was used to generate p-values. **C)** Tumour volumes from subcutaneous U87-MGvIII tumours intratumourally injected with saline, 2, 10, or 20 MBq $^{161}\text{Tb-DOTA-Z}_{\text{EGFR-03115}}$. The black arrow indicates the day of $^{161}\text{Tb-DOTA-Z}_{\text{EGFR-03115}}$ injection. The two-way ANOVA was used to generate p-values. **D)** Organ biodistribution of mice-bearing subcutaneous U87-MGvIII tumours intratumourally injected with 20 MBq $^{161}\text{Tb-DOTA-Z}_{\text{EGFR-03115}}$ at 24, 48, and 120 h post-injection. Data is presented as the % of injected activity normalised to organ weight. **E)** Representative IHC images showing H&E, Ki67, and p-histone $\gamma\text{H2A.X}$ staining from subcutaneous U87-MGvIII tumours treated with saline or 20 MBq $^{161}\text{Tb-DOTA-Z}_{\text{EGFR-03115}}$. **F)** Representative PET/CT images showing $^{89}\text{Zr-DFO-Z}_{\text{EGFR-03115}}$ uptake in orthotopic U87-MGvIII tumours treated with/without FUS+MB at 3 h post-intravenous injection. **G)** Brain biodistribution data and **H)** PET quantification of orthotopic U87-MGvIII tumours at 3 and 24 h after intravenous $^{89}\text{Zr-DFO-Z}_{\text{EGFR-03115}}$ injection. The unpaired t test was used to generate p-values.



Abstract Number: 23

Abstract Title: Metabolic heterogeneity in glioblastoma: correlating 18F-Fluciclovine PET uptake with RNA sequencing and metabolic pathway activity

Authors:

Kraya A², Rathi K², Li E¹, Scheuermann J¹, Young A¹, Schubert E¹, Aboian M², Doot R¹, Ware J¹, Pantel A¹, Amankulor N¹, O'Rourke D¹, Desai A¹, Nasrallah M¹, Brem S¹, Bagley S¹, **Nabavizadeh A¹**

¹University Of Pennsylvania, Philadelphia, United States, ²CHOP, Philadelphia, United States

Background

18F-fluciclovine PET monitors gliomas by evaluating amino acid metabolism; however, 18F-fluciclovine PET measures the glutamine pool which can vary between tumors and uptake can be lower in tumors with high conversion of glutamine to glutamate, leading to a low glutamine pool. This study investigates metabolic heterogeneity in glioblastoma (GBM) and correlates PET metrics with RNA sequencing

Material and Methods

Fifteen patients with recurrent GBM underwent 18F-fluciclovine PET imaging followed by surgical resection. Tumor percentage was determined by a neuropathologist. RNA was extracted from tumors, depleted of ribosomal content, and sequenced. RNA-Seq data were processed using the STAR-RSEM pipeline and normalized by TMM. Gene expression profiles were analyzed for metabolic, blood-brain barrier (BBB), and angiogenesis pathways using single-sample Gene Set Variation Analysis (ssGSVA). Fluciclovine uptake was modeled based on pathway activity, adjusted for tumor purity, and selected using Akaike Information Criterion (AIC). Separate analyses evaluated uptake as a function of BBB permeability (from DCE MRI), perfusion (CBV from DSC MRI), and tumor purity.

Results

SUVmax (20-30 minutes) was modeled using CBV, Kep mean, Kt mean, and tumor percentage in a multiple regression model (adjusted $R^2 = 0.89$; $p = 0.00026$). Blood-brain permeability (Kep mean) was significantly associated with 18F-fluciclovine uptake ($\beta = 10.24$, CI: 5.7–15, $p = 0.00068$). When 18F-fluciclovine levels were assessed as a function of RNA-Seq pathways by GLM (adjusted $R^2 = 0.76$; $p = 0.028$), uptake showed significant negative associations with tight junction ($\beta = -22.99$, $p = 0.026$), lipid biosynthesis ($\beta = -29.37$, $p = 0.010$), and glycolysis ($\beta = -20.26$, $p = 0.019$) pathway activity after adjusting for tumor purity.

Conclusion

18F-fluciclovine PET uptake is lower in tumors with high glycolysis and lipid biosynthesis. Tumors relying on glucose or glutamine for lipid production may have reduced intracellular glutamine, leading to lower PET tracer signal.

Author Disclosure: Nabavizadeh Ali, Advisory board for Telex and Consulting for Blue Earth Diagnostics.



Abstract Number: 24

Abstract Title: Dynamic 18F-Fluciclovine PET and MRI Metrics for Predicting Survival in Glioblastoma

Li E¹, Scheuermann J¹, Young A¹, Schubert E¹, Doot R¹, Ware J¹, Pantel A¹, Amankulor N¹, O'Rourke D¹, Desai A¹, Nasrallah M¹, Brem S¹, Bagley S¹, Nabavizadeh A¹

¹University Of Pennsylvania, Philadelphia, United States

Background

Glioblastoma is a heterogeneous and aggressive disease that recurs virtually in all cases. However improved prediction of survival may improve disease characterization and assist with treatment planning. We have previously shown that 18F-fluciclovine, a synthetic amino acid PET radiotracer, can be used to distinguish pseudoprogression and true progression of disease. In this study, we aimed to assess the value of MRI and dynamic 18F-fluciclovine PET in predicting survival and progression free survival (PFS) in the same cohort.

Material and Methods

30 patients with suspected radiographic recurrence of glioblastoma after first-line chemoradiotherapy underwent preoperative MRI and a 60-min 18F-fluciclovine PET. Tumors were then surgically resected for histopathologic evaluation.

From the MRI and 18F-fluciclovine PET, relative maximum cerebral blood volume (CBV_{max}) and maximum standardized uptake value (SUV_{max}), respectively were determined. Image-derived input functions were derived from the internal carotids, and a recovery coefficient was applied. Kinetic parameters (including specific volume of distribution, VS, ml/cm³) were measured via two-tissue compartment modeling. Parameter cutoffs were derived from receiver operating characteristic analyses aimed at determining histopathological progression. Kaplan-Meier curve plots and Cox proportional hazards models were generated with either one or two imaging metrics as covariates.

Results

Higher CBV_{max} (> 3.7) combined with lower VS (< 0.47) was associated with lower progression free survival hazards ratios of 3.37 [95%CI 1.15–9.88, p=0.027] and 2.79 [95%CI 1.04–7.47, p=0.041] respectively. Figure 1 shows the Kaplan-Meier plot when stratifying by CBV_{max} and VS. No other metrics were associated with survival or PFS.

Conclusion

High CBV_{max} and low 18F-fluciclovine VS were associated with reduced progression free survival. These findings suggest that combining dynamic 18F-Fluciclovine PET and MRI can be a promising tool to inform patient care and predict survival.



NMN Symposium: Precision Medicine

09 - 10. May 2025 / Vienna, Austria

Palais Ferstel

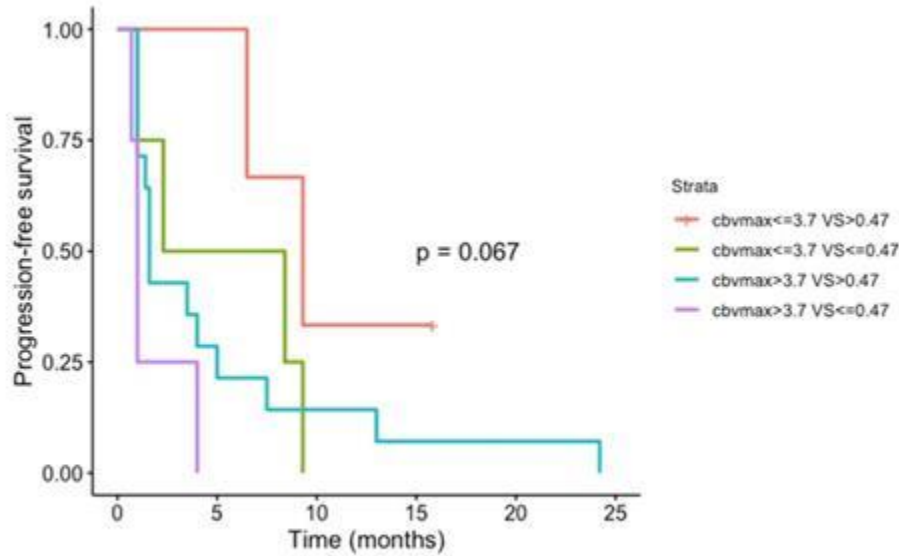


Figure 1: Progression-free survival curves stratified by MR (cbvmax) and ¹⁸F-Fluciclovine PET (Vs).

Author disclosure: Ali Nabavizadeh: Advisory board for Telix and consulting for Blue Earth Diagnostics.



Abstract Number: 25

Abstract Title: Imaging a potential lymphatic link between the intracranial and cervical compartments in patients receiving intracavitary radioimmunotherapy

Authors:

Roll W¹, Böning G², Schäfers M¹, Delker A², Stegger L¹, Zeidler R^{2,3}, Reulen H², Stummer W¹, Mütter M¹

¹University Hospital Münster, Münster, Germany, ²Ludwig-Maximilians-Universität, Munich, Germany,

³Helmholtz Munich, Munich, Germany

Background

The brain lymphatic system was discovered as an alternative way of metabolic clearance in the central nervous system. Previous studies reported on the presence of small lymphatic structures that exit the cranium. However, our current understanding of the brain lymphatic system is largely based on experimental animal studies, and reliable human in vivo imaging tools are lacking.

Material and Methods

Eight patients received 6A10-Fab fragments targeting carbonic anhydrase XII, labelled with lutetium-177 ([¹⁷⁷Lu]Lu-6A10-Fab), as part of the ongoing NOA-22 study (NCT05533242) or in a compassionate use setting before study initiation. After injection of [¹⁷⁷Lu]Lu-6A10-Fab into the resection cavity of glioblastoma patients, post-therapy whole body scans and SPECT/CT of the head were acquired from 2h to 7days post injection as part of a dosimetry protocol.

Results

In whole body scan and SPECT/CT of head and neck minor elevated uptake in the anatomical area of cervical lymph nodes ipsilateral to the injected resection cavity was observed in 50% of patients. The maximum uptake in cervical lymph nodes was detected 24-72 hours after injection. There was no obvious correlation of cervical lymphatic uptake and leakage of [¹⁷⁷Lu]Lu-6A10-Fab into cerebrospinal fluid. In all patients, resection cavity and injection reservoir contained the majority of the injected activity of [¹⁷⁷Lu]Lu-6A10-Fab.

Conclusion

Uptake of [¹⁷⁷Lu]Lu-6A10-Fab within the lymphatics of the neck may demonstrate an anatomical link between the intracranial compartment and the periphery. Intracavitary application of radionuclides may improve the understanding of spatial and temporal functionality of the brain lymphatic system. Further observations are needed to improve our understanding of the brain lymphatic system in glioblastoma.

Author Disclosure: Michael Mütter and Wolfgang Roll: advisory activities for ITM Isotope Technologies Munich SE.



Abstract Number: 26

Abstract Title: A Phase 1 trial to determine the maximum tolerated dose and patient-specific dosimetry of fractionated intracavitary radioimmunotherapy with Lutetium-177 labeled 6A10 Fab fragments in patients with glioblastoma – preliminary results from the first patient cohort

Authors

Müther M¹, Wolfgang R¹, Böning G², Gildehaus F², Delbridge C³, Albert N², Schäfers M¹, Delker A², Stegger L¹, Zeidler R^{2,4}, Reulen H¹, Stummer W¹

¹University Hospital Münster, Münster, Germany, ²Ludwig-Maximilians-Universität, Munich, Germany,

³Technical University, Munich, Germany, ⁴Helmholtz Munich, Munich, Germany

Objective

Following maximal safe resection and standard adjuvant radio- and chemotherapy, approved maintenance therapies for glioblastoma are lacking. Intracavitary radioimmunotherapy (iRIT) injected into the resection cavity offers a promising strategy for improving local tumor. This is an interim report of the NOA-22 study (NCT05533242).

Material and Methods

This prospective single-armed, multicenter phase 1 study, following a modified 3+3-design, provides data on the use of 6A10-Fab fragments targeting carbonic anhydrase XII, labelled with lutetium-177 ([¹⁷⁷Lu]Lu-6A10-Fab). Malignant glioma (WHO grades 3+4) after concomitant radio-chemotherapy and adjuvant standard chemotherapy with no or small residual disease are included. The injected activity is adapted to the volume of the resection cavity, resulting in a dose of 44Gy (cohort 1), 48Gy (cohort 2) and 52Gy (cohort 3). Primary study objective is to determine the maximum tolerated dose and safety of adjuvant radio-immunotherapy with [¹⁷⁷Lu]Lu-6A10-Fab.

Results

Three patients with glioblastoma concluded the first study cohort. No toxicities beyond grade 2 (CTCAE Version 5) were noted. One patient presented with a symptomatic increase in focal contrast enhancement and perifocal edema that decreased after a course of steroid treatment, consistent with therapy-associated changes. Dosimetry did not reveal absorbed doses above upper dose limits for organs at risk. All patients remain clinically stable and without tumor progression.

Conclusion

Intracavitary injection of [¹⁷⁷Lu]Lu-6A10-Fab appears to be feasible and safe. The study currently enrolls patients in a planned escalated dose scheme of 48 Gy cumulative dose in cohort 2.

Author Disclosure: Wolfgang Roll and Michael Müther: consulting activities for ITM Isotope Technologies Munich SE.



Abstract Number: 27

Abstract Title: Symptomatic prostate-specific membrane antigen (PSMA) PET-positive radionecrosis following multimodality brain metastasis-directed treatment including [177Lu]Lu-PSMA-617

Authors

Imber B¹, Kwok Hei Yu K¹, Abida W¹, Pike L¹, Grkovski M¹, Kaley T¹, Morris M¹, Bodei L¹, Nosov A¹, Dunphy M¹, Schoder H¹, Fox J¹, Rosenblum M¹, Bale T¹, Krebs S²

¹Memorial Sloan Kettering Cancer Center, New York, United States, ²Department of Nuclear Medicine, The University of Texas MD Anderson Cancer Center, Houston, United States

Background

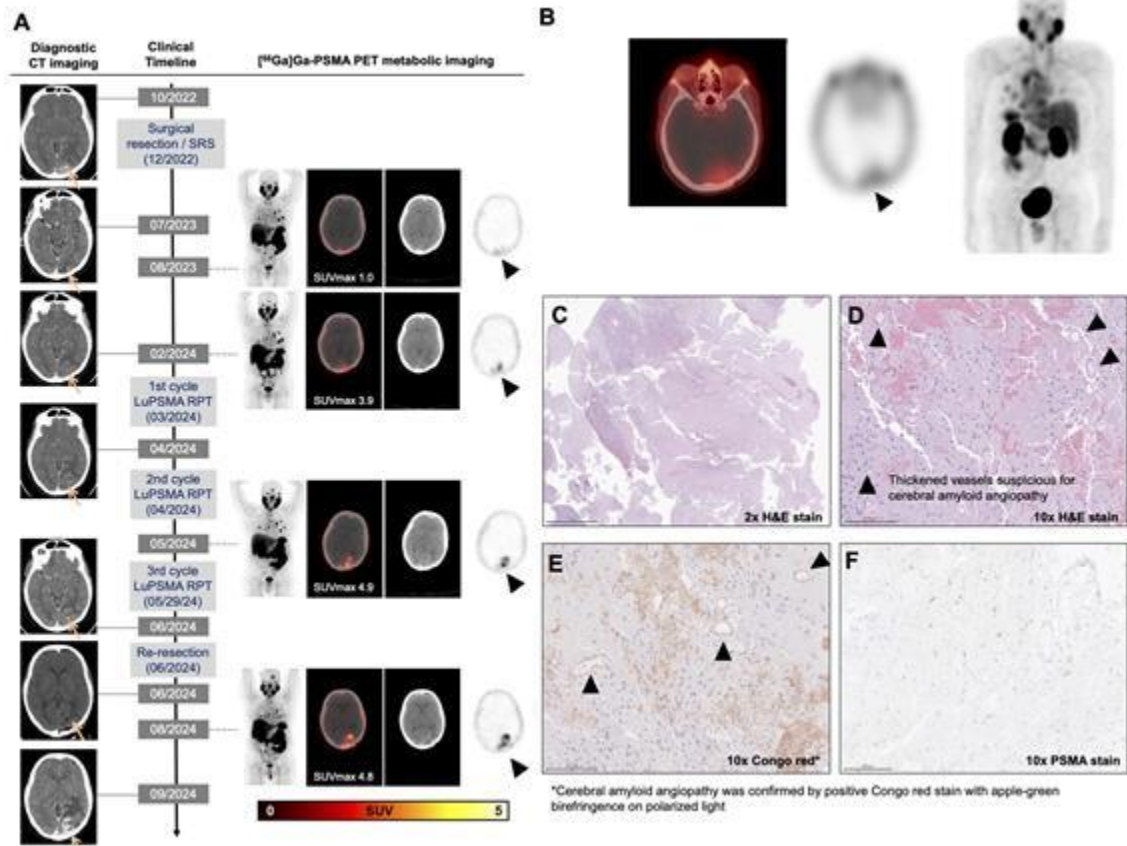
Prostate-specific membrane antigen (PSMA) theranostics have revolutionized prostate cancer treatment. There is considerable hope to utilize PSMA radiopharmaceutical therapy (PSMA-RPT) for brain metastases (BM). BM typically receive external beam radiotherapy as part of multimodality care; it is currently unclear if PSMA imaging can discriminate radionecrosis from tumor.

Methods/Results

A 65-year-old with MRI-incompatible pacemaker and metastatic prostate cancer to lung progressing on androgen deprivation therapy and enzalutamide, underwent resection of a left occipital dural brain metastasis (Figure A) and postoperative radiotherapy (30Gy, 5 fractions). [68Ga]Ga-PSMA-11 PET/CT imaging eight months later showed avid lung nodules but low-level intracranial uptake (SUVmax 1.0). Subsequent [68Ga]Ga-PSMA-11 PET/CT showed increased resection bed avidity (SUVmax 3.9); CT only revealed increased edema/gliosis. Given extracranial progression, he received [177Lu]Lu-PSMA-617 RPT; post-treatment SPECT/CT confirmed occipital PSMA uptake (Figure B). [68Ga]Ga-PSMA-11 PET/CT post-cycle 2 showed increasing peripheral radiotracer uptake (SUVmax 4.9), suspicious for viable tumor. Following RPT cycle 3, he experienced significant neurologic decline. Given clinical/radiographic suspicion for recurrent BM, he underwent re-resection with plan for salvage brachytherapy. However, histopathology revealed only necrosis (Figure C, D) and cerebral amyloid angiopathy (Figure E). Interestingly, PSMA immunohistochemistry in both the radionecrosis and amyloid was completely negative (Figure F). Postoperatively, he continues to face symptomatic radionecrosis; additional PSMA-RPT was deferred. Subsequent PET/CT showed persistent intracranial uptake (SUVmax 4.8) and increased lesion size (Figure A). He remains steroid dependent and is under evaluation for anti-angiogenic therapy.

Discussion/Conclusion

Discordance between PSMA imaging uptake and lack of PSMA immunostaining in the surgical specimen suggests the radiopharmaceutical accumulated nonspecifically in necrotic tissue. We speculate that continued [177Lu]Lu-PSMA-RPT exposure could contribute to or exacerbate radionecrosis and therefore be utilized cautiously in patients with prior brain irradiation and known radionecrosis risk factors. Our ongoing diagnostic study (NCT06209567) will further clarify the relationship between PSMA avidity and brain PSMA expression.



Author Disclosure: Imber, Brandon: reports research funding (to the institution) from Novartis, Kazia Therapeutics, and AstraZeneca, as well as other support from Bayer and personal fees and other support from GT Medical Technologies outside the submitted work. Abida, Wassim: received speaking honoraria from Roche, Pfizer, Medscape, Aptitude Health, Clinical Education Alliance, touchIME, and OncLive/MJH Life Sciences, consulting fees from Clovis Oncology, Janssen, ORIC Pharmaceuticals, Daiichi Sankyo, and AstraZeneca, and research funding (to his institution) from AstraZeneca, Zenith Epigenetics, Clovis Oncology, ORIC Pharmaceuticals, Epizyme, and Nuvation Bio. Pike, Luke: reports personal fees from Monograph Capital, DxCover, and Genece Health; and grants from Caris Life Sciences, Harbinger Health, and Delfi Diagnostics outside the submitted work. Morris, Michael: reports compensation for consulting with Lantheus, Daiichi, Convergent Therapeutics, Pfizer, ITM Isotope Technologies, Clarity Pharmaceuticals, Blue Earth Diagnostics, POINT Biopharma, Telix, Progenics, Z-Alpha, Ambrx, Flare Therapeutics, Fusion Pharmaceuticals, Curium, Transtherabio, Celgene, Arvinas, Core Medica, Exelixis, and Amgen. His institution receives research funding for clinical trials for Janssen, Novartis, Astellas, and AstraZeneca, and royalties from Telix. Bodei, Lisa: reports nonremunerated consultancy from Advanced Accelerator Applications, Ipsen, ITM, Iba, Great Point Partners, Point Biopharma, RayzeBio, Abdera, Fusion, Converge, Solve Tx, Amgen; Consultancy: Wren Laboratories; Research support (to the institution): Novartis. Krebs, Simone: reports consulting for Telix Pharmaceuticals Ltd.



Abstract Number: 28

Abstract Title: Intraarterial administration of peptide receptor radionuclide therapy in patients with advanced meningioma: initial safety and efficacy

Authors:

Amerein A¹, Maurer C², Kircher M¹, Gäble A¹, Krebold A¹, Rinscheid A³, Viering O¹, Pfob C¹, Bundschuh R^{1,4}, Behrens L², Braat A^{5,6}, Berlis A², Lapa C¹

¹Nuclear Medicine, Faculty of Medicine, University of Augsburg, Augsburg, Germany, ²Diagnostic and Interventional Neuroradiology, Faculty of Medicine, University of Augsburg, Augsburg, Germany, ³Medical Physics and Radiation Protection, University Hospital Augsburg, Augsburg, Germany, ⁴Department of Nuclear Medicine, University Hospital Carls Gustav Carus Dresden, Dresden, Germany, ⁵Radiology and Nuclear Medicine, University Medical Center Utrecht, Utrecht, The Netherlands, ⁶Nuclear Medicine, Netherlands Cancer Institute, Amsterdam, The Netherlands

Background

Peptide receptor radionuclide therapy (PRRT) is a treatment option for patients with advanced meningioma. Recently, intraarterial application of the radiolabeled somatostatin receptor agonists has been introduced as an alternative to standard intravenous administration. In this study, we assessed the safety and efficacy of intraarterial PRRT in patients with advanced, progressive meningioma.

Material and Methods

Patients with advanced, progressive meningioma underwent intraarterial PRRT with [¹⁷⁷Lu]Lu-HA-DOTATATE. The safety of PRRT was evaluated according to the Common Terminology Criteria for Adverse Events version 5.0. Treatment response was assessed according to the proposed Response Assessment in Neuro-Oncology (RANO) criteria for meningiomas in magnetic resonance imaging (MRI) and somatostatin receptor-directed PET/CT.

Results

Twenty patients (13 women, 7 men; mean age, 62 ± 13 y) with advanced meningioma underwent 1–4 cycles (median, 4 cycles) of intraarterial PRRT with [¹⁷⁷Lu]Lu-HA-DOTATATE (mean activity per cycle, 7,494 ± 268 MBq). Treatment was well tolerated with mainly grade 1–2 nephrotoxicity (30 % of all patients) and hepatotoxicity (45 % of all patients) and transient higher-grade hematotoxicity. Thirteen of 20 patients showed radiologic disease control at follow-up after therapy (1/20 complete remission, 1/20 partial remission, 11/20 stable disease), and 11 of 20 patients showed good control of clinical symptoms. In one patient, the catheter caused a carotid dissection during the angiography. Otherwise, the angiography was technically successful.

Conclusion

Intraarterial PRRT in patients with advanced meningioma is feasible and safe. It may result in improved radiologic and clinical disease control compared with intravenous PRRT. Further research to validate these initial findings and to investigate long-term outcomes is highly warranted.



Abstract Number: 29

Abstract Title: 18F-DOPA PET in Surgical Planning of High-Grade Gliomas: Volumetric Analysis, Comparison with intraoperative Fluorescence, and Histopathological Validation.

Authors:

Bianconi A^{1,2}, De Marco R², Pesaresi A², Morana G³, Bertero L⁴, Zotta M⁵, Morbelli S⁵, Bruno F⁶, Cofano F², Rudà R⁶, Garbossa D²

¹Neurosurgery, IRCCS Policlinico San Martino, Genova, Italy, ²Division of Neurosurgery, Dept of Neuroscience, Turin, Italy, ³Neuroradiology Unit, AOU Città della Salute e della Scienza, Turin, Italy, ⁴Pathology Unit, AOU Città della Salute e della Scienza, Turin, Italy, ⁵Nuclear Medicine Unit, AOU Città della Salute e della Scienza, Turin, Italy, ⁶Division of Neuro-Oncology, Dept of Neuroscience, Turin, Italy

Background

The extent of resection in high-grade gliomas, particularly of contrast-enhancing tumor (CET), is linked to improved patient survival. Recent studies suggest that extending resection beyond CET, such as into FLAIR hyperintense regions, may further enhance survival, provided it does not compromise functional outcomes. While FLAIR volumes are larger, amino acid PET scans, such as FDOPA-PET, often reveal smaller volumes that may extend beyond CET. This study investigates whether high Tumor-to-Non-Tumor Ratio (TNR) areas on FDOPA-PET, contain tumor cells and should be considered for resection.

Methods

A prospective study (ResPGlioma) was initiated in 2023, enrolling adults with newly diagnosed grade 4 gliomas who underwent FDOPA-PET within one week prior to surgery. FDOPA-PET scans were co-registered with contrast-enhanced T1-weighted and FLAIR MRI sequences. Prior to fluorescence-guided resection, five tissue samples were analyzed in five patients: CET (a), FLAIR+PET (b), PET only (c), FLAIR only (d), and areas with no evidence of disease on MRI (e). Histological analysis assessed five variables: presence of neoplastic, infiltrative, or normal/reactive tissue, percentage of necrosis, and mitotic count.

Results

Among 24 enrolled patients, mean tumor volumes were CET 27.42 cm³, FLAIR 65.89 cm³, and PET 30.81 cm³. Total resection of the PET volume, confirmed by post-operative MRI co-registered with pre-operative PET, was achieved in 44.4% of cases. The highest neoplastic component was found in samples (b) and (c), with sample (c) showing the greatest tumor proliferation (mean 22.8 mitoses per 10 high-power fields). This mitotic rate was higher in sample (c) compared to (b) and (d). Conversely, normal/reactive tissue was significantly lower in sample (c) compared to sample (d).

Conclusions

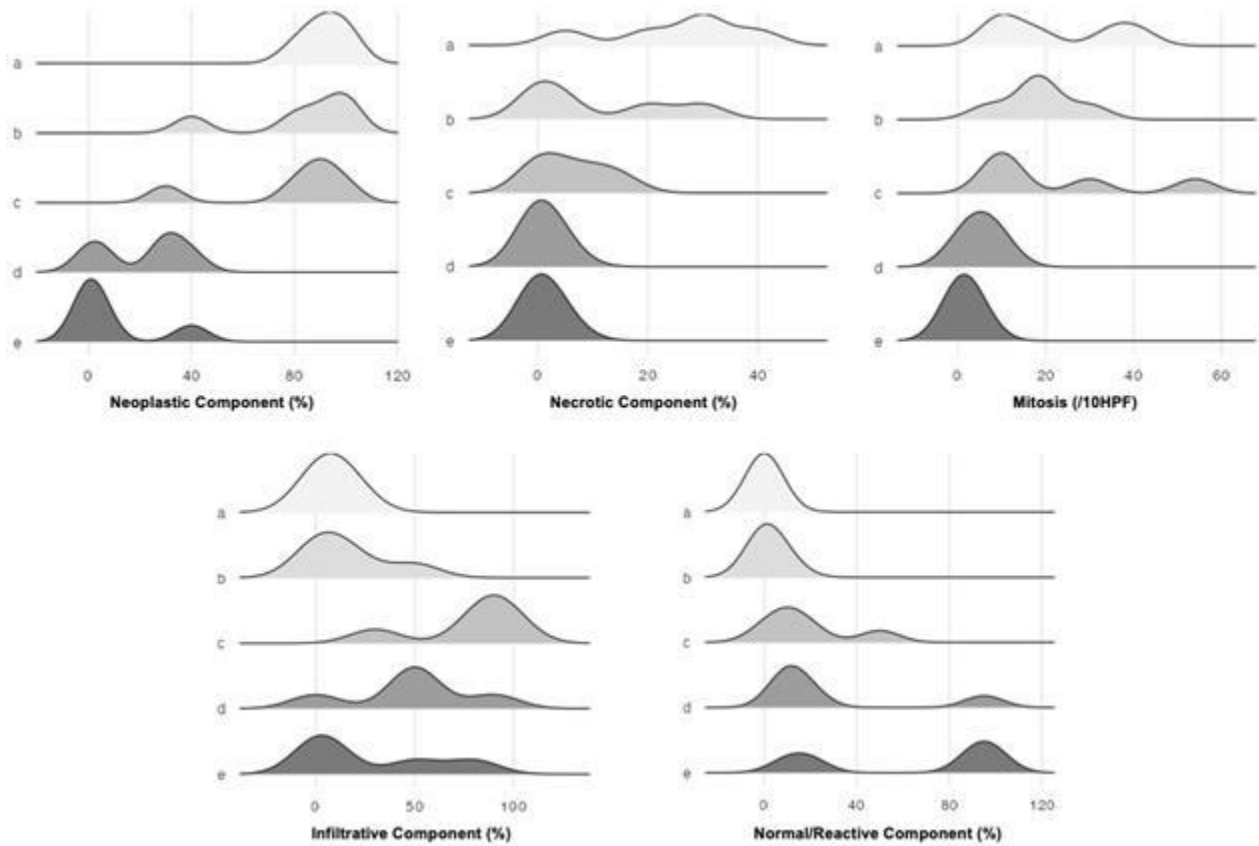
These findings highlight the importance of high-TNR areas on FDOPA-PET, suggesting they may serve as an alternative target for supramaximal resection. Future studies should explore whether these preliminary results correlate with improved survival outcomes.



NMN Symposium: Precision Medicine

09 - 10. May 2025 / Vienna, Austria

Palais Ferstel





Abstract Number: 30

Abstract Title: Validation of the PET-RANO Criteria in Pediatric Brain Tumors: Insights from FET-PET MRI Follow-Up

Authors:

Hedrich C¹, Nakuz T², Dorfer C³, Haberler C⁴, Kasprian G⁵, Madlener S¹, Eckert F^{6,7}, Rössler K³, Stepien N¹, Schned H¹, Aliotti Lippolis M¹, Mayr L¹, Azizi A¹, Peyrl A¹, Traub-Weidinger T^{2,8}, Gojo J¹

¹Department of Pediatrics and Adolescent Medicine, Comprehensive Center for Pediatrics and Comprehensive Cancer Center, Medical University of Vienna, Vienna, Austria, ²Division of Nuclear Medicine, Department of Biomedical Imaging and Image-Guided Therapy, Medical University of Vienna, Vienna, Austria, ³Department of Neurosurgery, Medical University of Vienna, Vienna, Austria, ⁴Division of Neuropathology and Neurochemistry, Department of Neurology, Medical University of Vienna, Vienna, Austria, ⁵Division of Neuroradiology and Musculoskeletal Radiology, Department of Biomedical Imaging and Image-Guided Therapy, Medical University of Vienna, Vienna, Austria, ⁶Department of Radiation Oncology, AKH, Comprehensive Cancer Center Vienna, Medical University Vienna, Vienna, Austria, ⁷Department of Radiation Oncology, University Hospital Tübingen, Tuebingen, Germany, ⁸Department of Diagnostic and Therapeutic Nuclear Medicine, Clinic Donaustadt, Vienna Health Care Group, Vienna, Austria

Background

Pediatric brain tumors present significant diagnostic challenges due to their biological and clinical diversity. While MRI is the gold standard for imaging, information on biological activity may be lacking and differentiation between active tumor tissue and non-tumor abnormalities may be difficult. [¹⁸F]-fluoroethyl-tyrosine positron emission tomography provides a more precise determination of metabolically active regions. The PET-RANO criteria, introduced in 2024, offer a standardized assessment of treatment response in gliomas based on changes in FET uptake, enhancing clinical decision-making. However, guidelines for practice in pediatric tumors are missing.

Material and Methods

This retrospective study includes twelve patients with different brain tumors (1 atypical teratoid/rhabdoid tumor, 1 myxopapillary ependymoma, 10 gliomas) younger than 18 years at the time of diagnosis (median 14 years, range 2-17 years, male to female ratio 1.4). All patients underwent multiple longitudinal FET-PET MRI scans as part of their routine clinical management, either for initial tumor evaluation or follow-up monitoring between 2018 and 2024. Forty FET-PET data sets were analyzed according to the 2024 PET-RANO criteria for validation and correlated with clinical outcomes, treatment decisions, and disease progression.

Results

RANO based changes in FET uptake, correlated with clinical outcomes (good correlation in 72.5% (n=29), uncertain correlation in 25% (n=10), no correlation in 0.25% (n=1). The re-evaluation of PET scans according to the PET-RANO criteria enabled clearer differentiation of treatment effects and tumor progression. Analyzed retrospectively, in 58% (n=7) of the patients, the definite treatment decisions were based on PET findings, and the application the PET-RANO criteria would have been of high clinical relevance in this cohort.

Conclusion

Longitudinal FET-PET MRI, in conjunction with the PET-RANO criteria, could be an essential tool for monitoring treatment response and tumor progression in pediatric brain tumors.



Abstract Number: 31

Abstract Title: 11C-Methionin PET for radiotherapy treatment planning in patients with rapid early progression after glioblastoma surgery: prospective phase II trial

Authors

Kazda T¹, Lakomy R, Hynkova L, Pospisil P, Hnidakova L, Vasina J, Belanova R, Prochazka T, Rehak Z, Adam J, Sana J, Selingerova I, Jancalek R, Fadrus P, Prochazkova K, Stepankova T, Lojova M, Slampa P

¹Masaryk Memorial Cancer Institute, Brno, Czech Republic

Background:

Radiotherapy (RT) is standard treatment for glioblastoma patients following initial surgery. Few retrospective studies indicate negative prognostic instances of progression during planning magnetic resonance (MR) (up to 1 week before initiating RT), termed Rapid Early Progression (REP). The optimal RT management for REP patients remains uncertain. The objective of this prospective phase II trial (NCT05608395) is to assess impact of 11C-Methionine PET used for RT planning in REP glioblastoma patients.

Material and Methods

We enrolled glioblastoma, IDHwt patients, who developed REP characterized by 1) increase in postoperative residuum by $\geq 25\%$, 2) appearance of new contrast enhancing lesion, 3) unequivocal progression of the unresected satellite. Patients received treatment based on the Stupp or Perry protocol. Treatment response was evaluated using RANO criteria. RT target volumes were delineated as follows: Gross tumor volume included tumor cavity, enhancing lesion and 11C-MET PET (1.3 tumor-to-background ratio). The clinical target volume was GTV plus a modified 2cm margin. The study is designed to demonstrate an increase in progression-free survival (PFS) from 4.9 months (historical cohort with median overall survival (OS) 10.7 months) to target PFS of 8 months.

Results

Out of 118 screened patients, total of 42 (35%) developed REP. The final results of the 31 enrolled patients (15 with Stupp protocol), with a median follow-up of 26.6 months, indicate no significant increase in PFS, with a median PFS of 3.5 months (13% at 12 months PFS). The median OS was 12.3 months comparing to 14.4. of historical REP cohort treated without MET PET navigation. During the conference secondary results will be shown as well.

Conclusion

11C-MET PET did not show significant benefit in target definitions for RT of glioblastoma patients with REP. Volumetric studies, patterns of failure and quality of life are important secondary outcomes revealing further research topics. Supported by NU20-03-00148 and NU22-03-00159.



Abstract Number: 32

Abstract Title: Expression of carbonic anhydrase type IX (CA IX) as target for radioligand therapy in gliomas and brain metastases

Authors:

Mair M^{1,2}, Tomasich E¹, Polten D¹, Greutter L³, Steindl A¹, Widhalm G⁴, Eckert F⁵, Wöhrer A³, Berghoff A¹, Preusser M¹, Albert N²

¹Division of Oncology, Department of Medicine I, Medical University of Vienna, Vienna, Austria, ²Department of Nuclear Medicine, LMU University Hospital, LMU Munich, Munich, Germany, ³Division of Neuropathology and Neurochemistry, Department of Neurology, Medical University of Vienna, Vienna, Austria, ⁴Department of Neurosurgery, Medical University of Vienna, Vienna, Austria, ⁵Department of Radiation Oncology, Medical University of Vienna, Vienna, Austria

Background

Radioligand therapies are approved in extracranial diseases such as neuroendocrine tumors or prostate cancer. However, their intracranial activity is largely unknown, and efficacy is challenged by intratumoral heterogeneity of target expression. Carbonic anhydrase type IX (CA IX) is investigated as target for radioligand therapies in renal cell carcinoma (RCC), but data on the expression in brain tumors are scarce.

Materials and Methods

Formalin-fixed, paraffin-embedded tumor samples of glioblastoma (isocitrate dehydrogenase [IDH]-wildtype, CNS WHO grade 4) and astrocytoma (IDH-mutant, CNS WHO grade 4), as well as tissue microarrays of RCC brain metastases (RCC-BM) were stained with rabbit anti-CA IX antibody (clone EP161, Cell Marque). CA IX expression was evaluated semiquantitatively.

Results

Overall, samples of 129 patients (55/129 [42.6%] glioblastoma, 22/129 [17.1%] astrocytoma, 52/129 [40.3%] RCC-BM) were included in this study. Median age at diagnosis was 59 years (range: 20 – 82), and 69/129 (53.5%) were male. Any CA IX immunoreactivity (either strong, intermediate, or weak) was seen in 51/55 (92.7%) glioblastoma, 19/22 (86.4%) astrocytoma, and 46/52 (88.5%) RCC-BM samples ($p = 0.588$). Strong CA IX immunoreactivity was most frequently observed in RCC-BM (26/52, 50.0%), followed by glioblastoma (21/55, 38.2%), and astrocytoma (2/22, 9.1%; $p = 0.003$). In gliomas, CA IX expression was observed mainly in pseudo-palisading tumor cells around necrotic foci and areas with microvascular proliferation. Of 17 patients with glioblastoma, paired samples at recurrence were available. Here, 9/17 (52.9%) showed an increase of CA IX expression at recurrence, whereas CA IX immunoreactivity decreased in 6/17 (37.5%) patients. There were no associations of CA IX expression with overall survival.

Conclusion

Given the expression of CA IX in most samples, CA IX could represent a promising target of radioligand therapies in gliomas and RCC-BM. CA IX-targeted PET studies are warranted to further evaluate inter- and intralesional heterogeneity guiding patient selection.

Author disclosure: Mair M: has received research funding from Bristol-Myers Squibb (modest) and travel support from Pierre Fabre (modest). Eckert F: has received speaker's honoraria or travel support from Dr. Sennewald Medizintechnik, Servier (speaker's honoraria, travel support). Berghoff A: has received research support from Daiichi Sankyo, Roche and honoraria for lectures, consultation or advisory board participation



Nuclear Medicine and Neurooncology (NMN)

NMN Symposium: Precision Medicine

09 - 10. May 2025 / Vienna, Austria

Palais Ferstel

from Roche, Bristol-Myers Squibb, Merck, Daiichi Sankyo, AstraZeneca, CeCaVa, Seagen, Alexion, Servier as well as travel support from Roche, Amgen and AbbVie. Preusser M has received honoraria for lectures, consultation or advisory board participation from Bayer, Bristol-Myers Squibb, Novartis, Gerson Lehrman Group (GLG), CNC Contrast, GlaxoSmithKline, Mundipharma, Roche, BMJ Journals, MedMedia, AstraZeneca, AbbVie, Lilly, Medahead, Daiichi Sankyo, Sanofi, Merck Sharp & Dohme, Tocagen, Adastr, Gan & Lee Pharmaceuticals, Janssen, Servier, Miltenyi, Boehringer Ingelheim, Telix, Medscape, OncLife. Albert N has received honoraria for lectures, consultation or advisory board participation from Novartis, Advanced Accelerator Applications, Telix Pharmaceuticals, OncLife, Medsir and Servier and research funding from Novocure and Telix Pharmaceuticals.



Abstract Number: 33

Abstract Title: Availability and use of PET in patients with brain tumours – a European Organisation for Research and Treatment of Cancer - Brain Tumour Group (EORTC-BTG) survey

Authors:

Mair M^{1,2}, Lohmann P^{3,4}, Cicone F⁵, Furtner J⁶, Galldiks N^{3,7}, Jakola A^{8,9}, Niyazi M¹⁰, Smits M^{11,12}, Tolboom N¹³, Verger A¹⁴, Le Rhun E¹⁵, Minniti G¹⁶, Weller M¹⁷, Preusser M², Albert N¹

¹Department of Nuclear Medicine, LMU University Hospital, Ludwig Maximilians University, Munich, Germany, ²Division of Oncology, Department of Medicine I, Medical University of Vienna, Vienna, Austria, ³Institute of Neuroscience and Medicine (INM-3, INM-4), Research Center Juelich, Juelich, Germany, ⁴Department of Nuclear Medicine, RWTH Aachen University Hospital, Aachen, Germany, ⁵Nuclear Medicine Unit, Department of Experimental and Clinical Medicine, "Magna Graecia" University of Catanzaro, Catanzaro, Italy, ⁶Research Center for Medical Image Analysis and Artificial Intelligence (MIAAI), Faculty of Medicine and Dentistry, Danube Private University, Krems, Austria, ⁷Department of Neurology, Faculty of Medicine and University Hospital Cologne, Cologne, Germany, ⁸Department of Neurosurgery, Sahlgrenska University Hospital, Gothenburg, Sweden, ⁹Institute of Neuroscience and Physiology, Department of Clinical Neuroscience, Sahlgrenska Academy, Gothenburg, Sweden, ¹⁰Department of Radiation Oncology, University Hospital Tuebingen, Tuebingen, Germany, ¹¹Department of Radiology & Nuclear Medicine, Erasmus MC, University Medical Centre Rotterdam, Rotterdam, The Netherlands, ¹²Brain Tumour Centre, Erasmus MC Cancer Institute, Rotterdam, The Netherlands, ¹³Department of Radiology and Nuclear Medicine, University Medical Centre Utrecht, Utrecht, The Netherlands, ¹⁴Department of Nuclear Medicine & Nancyclotep Imaging Platform, CHRU Nancy and IADI INSERM, UMR 1254, Université de Lorraine, Nancy, France, ¹⁵Department of Medical Oncology and Hematology, Brain Tumor Center, University Hospital and University of Zurich, Zurich, Switzerland, ¹⁶Department of Radiological Sciences, Oncology and Anatomical Pathology, Sapienza University of Rome, Rome, Italy, ¹⁷Department of Neurology and Brain Tumor Center, University Hospital and University of Zurich, Zurich, Switzerland

Background

PET is increasingly applied in neuro-oncology. However, data on the use across institutions and reasons for variable implementation are unknown.

Methods

From 12/06/2024 to 02/08/2024, a web-based survey on PET use in neuro-oncology was conducted among neuro-oncology centres of the EORTC Brain Tumour Group network.

Results

106 replies from 22 countries were recorded. Of these, 49 (46%) were from large-volume centres (>100 brain tumour patients/year), and 98 (93%) reported access to PET scanners (PET-CT, PET-MRI, PET only). However, PET was not performed in neuro-oncological care in 23 (23%) of these. Reasons for not performing PET (n=30; 1 not reported [n.r.]) included unavailable tracers (15/30, 50%), high costs (11/30, 37%), PET considered unnecessary (9/30, 30%), insufficient slots (4/30, 13%), no reimbursement (4/30, 13%), lack of expertise for PET interpretation (3/30, 10%), or other/unknown (3/30, 10%). Of centres performing PET (n=74; 1 n.r.), 70/74 (95%) reported use in glioma, 59/74 (80%) in brain metastasis, 53/74 (72%) in meningioma, and 47/74 (64%) in CNS lymphoma. Amino acid PET was performed at 63/72 (88%, 2 n.r.) centres, predominantly in glioma (59/60, 98%; 3 n.r.) and brain metastasis (45/60, 75%). Indications included differentiation of treatment-related changes from tumour progression (59/60, 98%), differential diagnosis (55/60, 92%), and hotspot delineation



NMN Symposium: Precision Medicine

09 - 10. May 2025 / Vienna, Austria

Palais Ferstel

(48/60, 80%). Somatostatin receptor (SSTR) PET was performed at 51/69 (74%) centres, mainly in meningioma (49/50, 98%; 1 n.r.). Here, main indications were patient selection for radioligand therapy (41/50, 80%), radiotherapy target volume definition (33/50, 65%), and differential diagnosis (28/50, 55%). Unrestricted coverage by statutory health insurances was reported by 47/60 (78%) centres for amino acid and 34/50 (77%) for SSTR PET.

Conclusion

Availability, use, and reimbursement policies of PET for neuro-oncology are highly variable across Europe. Generation of high-quality evidence demonstrating clinical benefit is needed to facilitate implementation, regulatory approval, and coverage by health insurance.

Author disclosure: Mair M has received research funding from Bristol-Myers Squibb and travel support from Pierre Fabre. Lohmann P has received honoraria for lectures from Blue Earth Diagnostics, and for advisory board participation from Servier. Furtner J has received honoraria for lectures, consultation or advisory board participation from Novartis, Seagen, Sanova, Servier. Galldiks N has received honoraria for lectures from Blue Earth Diagnostics, for advisory board participation from Telix Pharmaceuticals and Servier, and for consultancy services from Telix Pharmaceuticals. Smits M has received consultancy fees from Bracco (paid to institution) and speaker fees from the European School of Radiology (paid to institution). Niyazi M received speaker honoraria from Brainlab and Astra Zeneca. Tolboom N has received honoraria for advisory board participation and consultancy services from Telix Pharmaceuticals and receives in kind research support from Curium Pharma. AV has received honoraria for lectures and advisory board participation from Curium, Eisai, General Electrics and Novartis. Le Rhun E has received research grants from Bristol Meyers Squibb (BMS), and honoraria for lectures or advisory board participation or consulting from Astra Zeneca, Daiichi, Bayer, Biodexa/Sitoxi, Janssen, Leo Pharma, Pfizer, Pierre Fabre, Roche, Seattle Genetics and Servier. Minniti G has received honoraria for lectures, consultation or advisory board participation from the following for-profit companies: Brainlab, Accuray, Servier, Astra-Zeneca, Novocure, Pfizer Weller M has received research grants from Novartis, Quercis and Versameb, and honoraria for lectures or advisory board participation or consulting from Anheart, Bayer, Curevac, Medac, Neurosense, Novartis, Novocure, Orbus, Pfizer, Philogen, Roche and Servier. Preusser M has received honoraria for lectures, consultation or advisory board participation from Bayer, Bristol-Myers Squibb, Novartis, Gerson Lehrman Group (GLG), CNC Contrast, GlaxoSmithKline, Mundipharma, Roche, BMJ Journals, MedMedia, AstraZeneca, AbbVie, Lilly, Medahead, Daiichi Sankyo, Sanofi, Merck Sharp & Dohme, Tocagen, Adastra, Gan & Lee Pharmaceuticals, Janssen, Servier, Miltenyi, Boehringer Ingelheim, Telix, Medscape, OncLife. Albert N has received honoraria for lectures, consultation or advisory board participation from Novartis, Advanced Accelerator Applications, Telix Pharmaceuticals, OncLife, Medsir and Servier and research funding from Novocure and Telix Pharmaceuticals. All other authors report no conflicts of interest related to the present work.



Abstract Number: 34

Abstract Title: How we can change scanning parameters but maintain image quality

Authors:

Gromova E¹, Kataeva G¹, Susin D¹, Kovalev K¹

¹Ldc Mibs, Saint-petersburg, Russian Federation

Aim/Introduction

PET-CT FET is an important technique in monitoring the treatment brain tumors. According to EANM guidelines the standard protocol PET-CT with FET is static scanning from 20 to 40 minutes after injection. We studied 117 patients from 8 to 73 years with different degrees of pathological hyperfixation FET in brain: 74 patients - glioma of varying degrees of malignancy, 43 patients - secondary brain damage, 51 patients did not receive any treatment; 66 patients received different types of treatment.

Materials and Methods


PET-CT protocol: start scanning 20 min after injection; scanning time is 20 minutes in list-mode; reconstruction of data: from 20 to 40 - «standard», from 20 to 30 - «early» and from 30 to 40 minutes - «late» images. The assessment was carried out using a semi-quantitative method - with the calculation of TBRmax and TBRpeak.

Results

Based on a comparison of «early» and «late» images it was found that regardless of the type of tumor and the type of treatment performed in the lesions the values of all parameters do not differ significantly while in the cortex. In routine practice we can reduce the scanning time to 10 minutes with the period from 20 to 30 minutes after injection being preferable because TBRmax during this period is comparable to that from 20 to 40 minutes.

Conclusion

1. make the examination more comfortable for patients and reduce the risk of movement artifacts taking into account that the severity of the patient's condition does not allow them to maintain a stationary position for a long time; 2. reduce the time of anesthesia and the dose of medication when scanning children which will increase the safety of the study for them; 3. increase the cost-effectiveness of the PET-CT procedure due to the ability to scan a larger number of patients in a shorter time



Abstract Number: 35

Abstract Title: Role of PET FET in monitoring of treatment brain metastasis

Authors:

Gromova E¹, Kataeva G¹, Kovalev K¹, Susin D¹

¹Ldc Mibs, Saint-petersburg, Russian Federation

The main method of radiosurgical treatment of secondary lesions is the Gamma-Knife. In connection with the development of radiosurgical treatment, the problem of differential diagnosis of continued tumor growth and post-radiation changes becomes relevant.

We examined 73 patients with brain metastases of various types of cancers. All patients underwent MRI and PET FET. PET-CT was performed according to the standard protocol. The evaluation of PET images was carried out by a semi-quantitative method - TBR max.

Differences in TBR max and the number of metastases in these groups are not significant, as well as, according to the Kaplan-Meier analysis, differences in the duration of the relapse-free period. However, differences in the duration of the relapse-free period in the groups after a single (Median, Q1; Q3) (12.9, 10.5; 24.4) or multiple (7.5, 3.5; 10.5) radiosurgical treatment are significant (Gehan's Wilcoxon Test, Test statistic = 2.063905 p = .03903).

Based on the analysis of the data obtained, it was found that the threshold value TBR max ≥ 2.8 in 100% of cases indicates progression, TBR max ≤ 1.7 indicates a stable course. Whereas TBR max in the range from 1.7 to 2.8 (in 33 people from the examined group, i.e. in 50% of all cases) may indicate both progression and post-radiation changes, as well as confirmed positive dynamics.

Thus, we confirmed that the numerical value of TBR max is a relative indicator. And when interpreting PET data, we cannot rely only on the TBR max value in the range from 1.7 to 2.8 if we did not have PET before treatment. In the absence of other markers of the development of progression (for example, the appearance of new pathological foci), to assess the dynamics and confidently identify post-radiation changes, a repeat PET should be prescribed after 2-3 months with a preliminary MRI.



Abstract Number: 36

Abstract Title: A prospective phase I study of adjuvant [¹⁷⁷Lu]Lu-PSMA-617 for PSMA-expressing IDH wildtype gliomas following chemoradiotherapy

Authors:

Imber B¹, Jackson C¹, Young R¹, Humm J¹, Grkovski M¹, Bale T¹, Miller A², Mellinghoff I¹, Krebs S³, Schoder H¹, Kaley T¹

¹Memorial Sloan Kettering Cancer Center, New York, United States, ²NYU Grossman School of Medicine, New York, United States, ³University of Texas, MD Anderson Cancer Center, Houston, United States

Background

Prostate specific membrane antigen (PSMA)-directed therapeutics have revolutionized treatment of metastatic prostate cancer. However, this target is expressed by numerous tumor histologies. Given potential for strong PSMA expression within glioma neovasculature, we are exploring a PSMA-anchored adjuvant theranostic strategy incorporating PSMA PET imaging and radiopharmaceutical therapy (RPT) for malignant glioma neovessels and microscopic disease.

Materials/Methods

This is a phase I, trial-in-progress of adjuvant [¹⁷⁷Lu]Lu-PSMA-617 for newly diagnosed, isocitrate dehydrogenase (IDH) wildtype gliomas following upfront standard-of-care temozolomide and external beam radiotherapy (EBRT). The primary outcome is safety, and primary endpoint is descriptive toxicity during and up to 8 weeks post first infusion of [¹⁷⁷Lu]Lu-PSMA-617. Eligible patients have grade II-IV glioma that is IDH1-R132H wildtype with immunohistochemistry confirmation of PSMA expression.

Eligible patients will first undergo screening including [⁶⁸Ga]Ga-PSMA-PET/MR scan performed 2 weeks post-EBRT (Figure). If PSMA avidity exceeds background brain parenchyma, the patient will receive 2 cycles of 7.4GBq of [¹⁷⁷Lu]Lu-PSMA-617 spaced 4 weeks apart, in combination with standard adjuvant temozolomide (150-200 mg/m² per cycle). Dosimetric assessment will be performed during the first cycle of [¹⁷⁷Lu]Lu-PSMA-617 RPT, including serial single photon emission CT (SPECT) imaging of the head. Four weeks post-cycle 2, patients will undergo repeat [⁶⁸Ga]Ga-PSMA-PET/MR. If residual PSMA avidity above background, patients can receive up to 4 additional monthly cycles of [¹⁷⁷Lu]Lu-PSMA-617 spaced 4 weeks apart, in combination with standard adjuvant temozolomide. Patients will undergo regular safety assessments, frequent bloodwork, quality of life surveys and imaging every 2 months. A second [⁶⁸Ga]Ga-PSMA-PET scan will be performed at progression.

Discussion/Conclusion

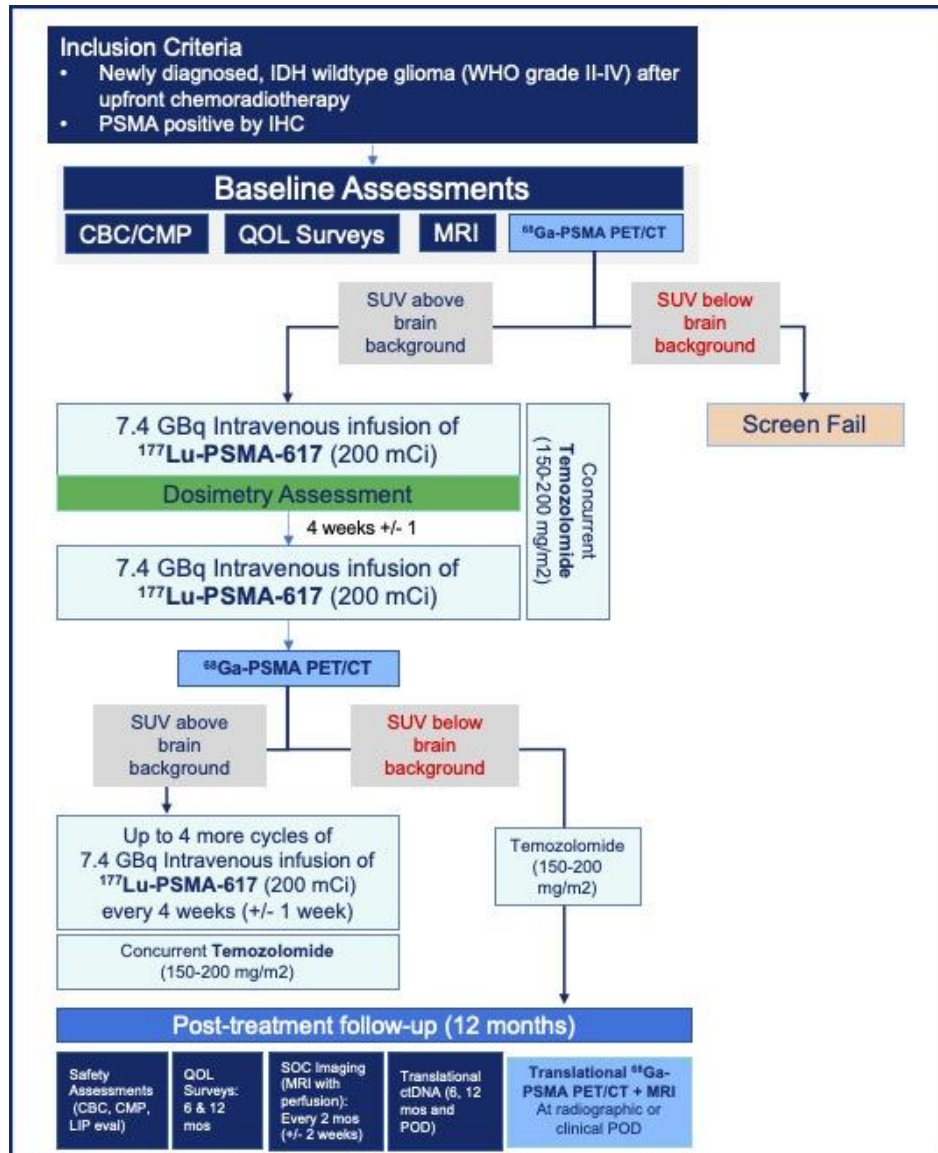
This phase I study offers a novel approach to integrate RPT for a disease with substantial unmet need. The trial is undergoing IRB approval and slated to open at our institution in the next month. At the symposium, we will share detailed study design and early patient experience/data.



NMN Symposium: Precision Medicine

09 - 10. May 2025 / Vienna, Austria

Palais Ferstel



Author Disclosure: Imber, Brandon: reports research funding (to the institution) from Novartis, Kazia Therapeutics, and AstraZeneca, as well as other support from Bayer and personal fees and other support from GT Medical Technologies outside the submitted work. Krebs, Simone: reports consulting for Telix Pharmaceuticals Ltd. Mellinghoff, Ingo: reports receiving personal fees (advisory board services) from Agios, Black Diamond Therapeutics, Debiopharm Group, Erasca, Novartis, Prelude Therapeutics, Roche Therapeutics, Servier Pharmaceuticals, Voyager and grants from General Electric and Puma Biotechnology. Other authors: None.



Abstract Number: 37

Abstract Title: Expanding the role of [18F]FET PET-MRI beyond glioma: superior detection of small functional pituitary tumors.

Authors:

Pruis I^{1,2}, Verburg F¹, Balvers R³, Harteveld A¹, Neggers S⁴, Refardt J⁴, Veldhuijzen van Zanten D^{1,2}

¹Dept. of Radiology & Nuclear Medicine, Erasmus MC – University Medical Centre Rotterdam, Rotterdam, Netherlands, ²Brain Tumour Centre, Erasmus MC Cancer Institute, Rotterdam, Netherlands, ³Dept. of Neurosurgery, Erasmus MC – University Medical Centre Rotterdam, Rotterdam, Netherlands, ⁴Dept. of Internal Medicine - Endocrinology, Erasmus MC – University Medical Centre Rotterdam, Rotterdam, Netherlands

Background

Functional pituitary tumors, though typically <6 mm, often cause severe and diverse symptoms, leading to early mortality. Standard diagnostic approaches - including laboratory tests, MRI, and, if needed, inferior petrosal sinus sampling (IPSS) - fail to identify the hormone-secreting source in up to 40% of patients. This diagnostic uncertainty excludes patients from curative surgery or gamma-/cyberknife therapy. This study evaluates the diagnostic yield of [18F]FET PET-MRI for detecting these elusive tumors.

Materials and Methods

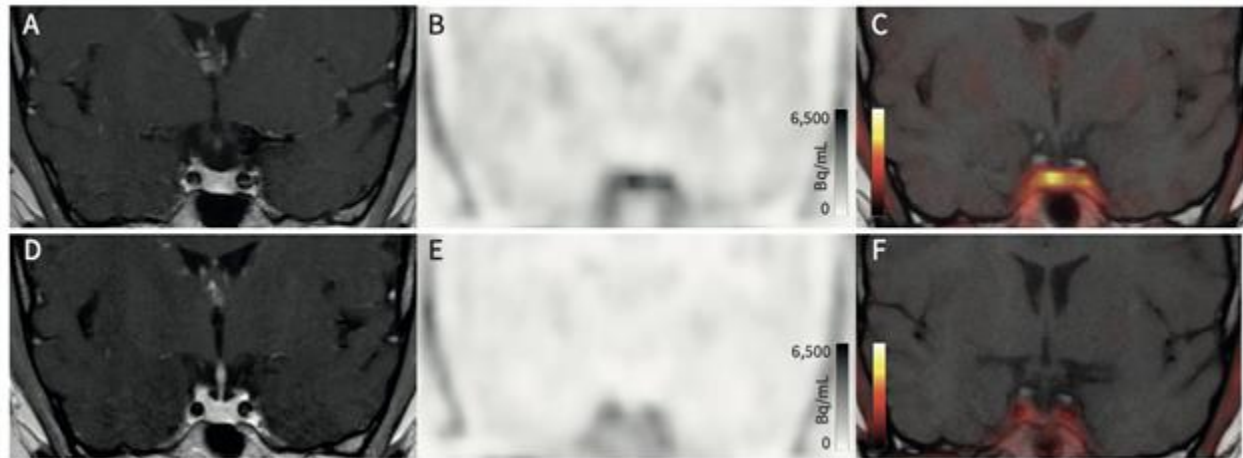
This retrospective study included patients with suspected pituitary adenomas but previously negative or inconclusive MRIs. Patients underwent [18F]FET PET-MRI between February 2021 and December 2024. Hybrid PET-MRI and MRI-only images were independently evaluated by blinded expert neuroradiologists and nuclear medicine physicians. When available, post-operative tissue analysis served as the reference standard for sensitivity and positive predictive value (PPV). Findings were compared to previous MRI, IPSS, and clinical/biochemical follow-up.

Results

A total of 103 scans in 78 patients were analyzed. An earlier case series of 22 patients (68% female, mean age 48±15 years) demonstrated a clear metabolic focus in all cases. Surgery was performed in 15 patients, confirming a corticotroph pituitary tumor in 10/15 cases and a pituitary tumor in 1/15, yielding a sensitivity of 100% and a PPV of 73%. Lateralization accuracy surpassed IPSS in 33% of cases. Among treated patients, 75% achieved symptom remission and biochemical normalization (Fig_1).

Conclusion

Preliminary clinical data indicate that [18F]FET PET-MRI enhances the detection and localization of small functional pituitary tumors. Ongoing internal and external validation in international cohorts is expected to confirm these findings, with results anticipated by April 2025.



Fig_1 Example case pre- (top row) and post-surgery (bottom row). T1-weighted post-gadolinium MRI (A, D) shows no lesion, while [18F]FET PET (B, E) and fused PET-MRI (C, F) initially reveal a focal lesion, with no residual uptake post-surgery.



Abstract Number: 38

Abstract Title: Tumor dosimetry in patients receiving [177Lu]Lu-DOTATATE treatment for recurrent meningioma

Authors:

Mair M^{1,2}, Delker A¹, Stoecklein V³, Wiegand L¹, Wehn A³, Wenter V¹, Zacherl M¹, Preusser M², Brendel M¹, Harter P^{4,5,6}, Schichor C³, Albert N^{1,5,6}

¹Department of Nuclear Medicine, LMU University Hospital, Ludwig Maximilians University, Munich, Germany,

²Division of Oncology, Department of Medicine I, Medical University of Vienna, Vienna, Austria, Vienna, Austria,

³Department of Neurosurgery, LMU University Hospital, Ludwig Maximilians University, Munich, Germany,

⁴Center of Neuropathology and Prion Research, Faculty of Medicine, LMU Munich, Munich, Germany,

⁵Bavarian Cancer Research Center (BZKF), Partner Site Munich, Munich, Germany, ⁶German Cancer Consortium (DKTK), Partner Site Munich, Munich, Germany

Background

Radionuclide therapy using [177Lu]Lu-DOTATATE has shown disease stabilization in small studies of recurrent meningioma, and the randomized LUMEN-1 (EORTC-2334) trial is ongoing in this indication. However, data on dosimetry are scarce.

Methods

Patients with recurrent meningioma treated with [177Lu]Lu-DOTATATE were retrospectively identified. Post-treatment 177Lu-SPECT/CT was performed 24, 48 and 72 hours after [177Lu]Lu-DOTATATE administration. Lesion dosimetry was performed with MIM SurePlan MRT using PETEdge+ segmentation on SPECT 24h p.i. and a mono-exponential fit model.

Results

In total, 14 patients were included (7 [50.0%] female; median age at first administration 55 years [range: 33-82]). The cohort comprised 4 patients with CNS WHO grade 1 (28.6%), 5 patients with grade 2 (35.7%), and 4 patients with grade 3 (28.6%), while grade was unknown in one patient. In median, patients had 2 resections (range: 1-5) and 1 course of radiotherapy (range: 0-4) before [177Lu]Lu-DOTATATE treatment, whereas no patient received prior systemic therapy. Overall, 48 cycles were administered (median per patient: 4 cycles [range: 2-8]) with a median activity of 7.8 GBq (range: 7.0-8.1). Data for dosimetry calculation was available in 27 cycles, and the median number of segmentable lesions per patient was 2.5 (range: 1-9). The median tumor-absorbed dose (TAD) per cycle was 0.3 Gy/GBq (range: 0.0-2.8), and median effective tumor half-life was 26 hours (range: 8-63). TAD in the first cycle was higher in CNS WHO grade 3 tumors (median: 1.4 Gy/GBq [range: 0.1-2.8]) compared to grade 1 (median: 0.4 Gy/GBq [range: 0.0-1.3]; p=0.023) and grade 2 (median: 0.3 Gy/GBq [range: 0.0-0.8]; p=0.008). No changes in TAD over time were observed (p=0.8). Data on associations with outcome and pre-treatment PET will be presented at the meeting.

Conclusion

In our cohort, TAD was associated with CNS WHO grade. Prospective trials are needed to define efficacy and dose-response relationships of [177Lu]Lu-DOTATATE in meningioma.

Author disclosure: Mair M has received research funding from Bristol-Myers Squibb and travel support from Pierre Fabre. Preusser M has received honoraria for lectures, consultation or advisory board participation from Bayer, Bristol-Myers Squibb, Novartis, Gerson Lehrman Group (GLG), CNC Contrast, GlaxoSmithKline,



Nuclear Medicine and Neurooncology (NMN)

NMN Symposium: Precision Medicine

09 - 10. May 2025 / Vienna, Austria

Palais Ferstel

Mundipharma, Roche, BMJ Journals, MedMedia, AstraZeneca, AbbVie, Lilly, Medahead, Daiichi Sankyo, Sanofi, Merck Sharp & Dohme, Tocagen, Adastr, Gan & Lee Pharmaceuticals, Janssen, Servier, Miltenyi, Boehringer Ingelheim, Telix, Medscape, OncLive. Brendel M: Consultant/Advisory Board: Life Molecular Imaging, GE Healthcare, MIAC; Honoraria: Iba, Life Molecular Imaging, GE Healthcare, Roche. Albert N has received honoraria for lectures, consultation or advisory board participation from Novartis, Advanced Accelerator Applications, Telix Pharmaceuticals, OncLife, Medsir and Servier and research funding from Novocure and Telix Pharmaceuticals. .



Abstract Number: 39

Abstract Title: Probing the advantage of immuno-PET In advancing clinical theranostics for high-grade gliomas: A scoping review

Authors:

Ibiyo M^{1,2}, Rahamon S², Kolade O¹

¹Department of Nuclear Medicine, University College Hospital Ibadan Nigeria, Ibadan, Nigeria, ²Department of Immunology, Faculty of Basic Medical Sciences, University of Ibadan, Ibadan, Nigeria

Immuno-positron emission tomography (Immuno-PET) is a non-invasive molecular imaging technique that takes advantage of the combinatory sensitivity of PET and the specificity of monoclonal antibodies to visualize and understand the tumour microenvironment (TME) for disease prognostication and identification of potential therapeutic targets. Antibody-based and radionuclide therapeutic studies have not delivered much impact in managing high-grade gliomas as anticipated. Glioma care is yet to evolve with the same strength as treatment advances experienced with other solid tumours. The value of immuno-PET in theranostic imaging of high-grade gliomas for prognostication and identifying future targets for combination therapies is worth exploring.

A search was conducted using the PRISMA-ScR checklist as a guide. Relevant publications between 2005 and 2025 from five databases were obtained using the keywords: immuno-PET, antibody-based PET, radiotracer, glioma, and theranostic. Titles and abstracts of all study designs and hand-searched references, with duplicates excluded, were used for full-text analysis and data extraction.

Molecular targets in TME such as the epidermal growth factor receptor (EGFR), vascular endothelial growth factor (VEGF), specific cell differentiation markers like CD 146, CD 11a and 11b, immune checkpoint inhibitors like PD-L1, and prostate-membrane specific antigen (PSMA), and engineered affibody molecules have been demonstrated to be effective targets for immuno-PET in glioma imaging studies. Some radioligands/radio-conjugates including ²¹³Bi-DOTA-substance P, ⁹⁰Y-DOTATOC, ¹¹¹In-DTPA, ¹⁸F-FET, ¹⁸F-GE-180, p-[¹³¹I]-iodo-L-phenylalanine, PSMA, and ⁸⁹Zr/¹⁷⁷Lu-labeled Lumi804-αCD11b, have been studied and found to have varied utility including improved target-to-background ratio compared to MRI studies. Larger studies, especially clinical trials and in situ studies need to be undertaken for integrative assessment of functional outcomes and patients' quality of life, to inclusively democratize current findings and advance the frontiers of precision care for glioma patients.

Immuno-PET holds promising applications for the diagnosis and treatment of high-grade gliomas.

Author disclosure: Morohunmubo Ibiyo: Nil.



Abstract Number: 40

Abstract Title: PSMA PET uptake patterns in brain tumors: comparative analysis of [68Ga]Ga-PSMA-11/[18F]PSMA-1007 PET with [18F]FET PET and contrast-enhanced MRI

Authors:

Mair M^{1,2}, Holzgreve A^{1,3}, Delker A¹, Wenter V¹, Zacherl M¹, Preusser M², Harter P⁴, Brendel M¹, Thon N^{5,6}, von Baumgarten L⁵, Albert N¹

¹Department of Nuclear Medicine, LMU University Hospital, LMU Munich, Munich, Germany, ²Division of Oncology, Department of Medicine I, Medical University of Vienna, Vienna, Austria, ³Ahmanson Translational Theranostics Division, David Geffen School of Medicine at UCLA, Los Angeles, USA, ⁴Institute of Neuropathology, Faculty of Medicine, LMU Munich, Munich, Germany, ⁵Department of Neurosurgery, LMU University Hospital, LMU Munich, Munich, Germany, ⁶Department of Neurosurgery, Knappschaft University Hospital Bochum, Bochum, Germany

Background

[177Lu]Lu-PSMA-617 therapy is approved in metastatic prostate cancer. While expression of PSMA has been observed in brain tumors, systematic data on uptake patterns of PSMA PET in relation to amino acid PET and contrast-enhanced MRI are scarce.

Methods

Patients with brain tumors who underwent [68Ga]Ga-PSMA-11 and/or [18F]PSMA-1007 PET were included in this single-center retrospective study. PSMA PET-positive volume (PSMA+) was segmented as any volume with SUV > blood pool activity, while [18F]FET PET-positive volume (FET+) was defined as SUV >1.6x SUVmean of background. Contrast-enhancing volume in MRI (CE+) was segmented manually.

Results

In total, 15 patients (9 [60.0%] glioblastoma, 4 [26.7%] isocitrate dehydrogenase (IDH)-mutant glioma, 2 [13.3%] prostate cancer brain metastases [BM]) with 28 lesions were included. In PSMA PET, the highest SUVmax values were observed in BM (median 2.5, range: 2.2-2.8), followed by glioblastoma (1.8 [1.0-5.6]) and IDH-mutant glioma (1.0 [0.1-2.3]); p=0.029), as were TBRmax values (BM: 3.1 [2.2-4.0]; glioblastoma: 3.0 [1.1-12.0]; IDH-mut glioma: 0.8 [0.1-2.9]; p = 0.002). Overall, uptake intensities (SUVmax, TBRmax) were higher in FET PET than PSMA PET (p=0.001). Furthermore, FET+ exceeded PSMA+ volumes (median: 4.95 ml [0-115.00] vs. 4.60 ml [0-77.20]; p=0.041), while no difference was found between PSMA+ and CE+ volumes (median: 1.73 ml [0-70.50]; p = 0.515). Only partial volume overlaps were observed, as Dice coefficients were 0.398 [0.016-0.696] for PSMA+/FET+ and 0.376 [0.043-0.784] for PSMA+/CE+ in glioblastoma, as well as 0.405 [0.030-0.611] for PSMA+/FET+ and 0.182 [0-0.522] for PSMA+/CE+ in IDH-mutant glioma. In glioblastoma, PSMA+/FET+ overlaps accounted for a median of 33.9% [0.8%-99.5%] of FET+ volumes, whereas PSMA+/CE+ overlaps were 51.6% [0.2%-94.1%] of CE+ volume.

Conclusion

PSMA uptake is highly variable and mainly found in CE+ volume with disrupted BBB. As metabolically active FET+ volumes exceed PSMA+ volumes, methods to open the BBB should be evaluated for theranostic applications.

Author disclosure: Mair M has received research funding from Bristol-Myers Squibb (modest) and travel support from Pierre Fabre (modest). AH reports compensation for scientific consulting by ABX advanced



Nuclear Medicine and Neurooncology (NMN)

NMN Symposium: Precision Medicine

09 - 10. May 2025 / Vienna, Austria

Palais Ferstel

biochemical compounds outside the submitted work, and is funded by the Deutsche Forschungsgemeinschaft (DFG, German Research Foundation) – 545058105. Preusser M has received honoraria for lectures, consultation or advisory board participation from Bayer, Bristol-Myers Squibb, Novartis, Gerson Lehrman Group (GLG), CNC Contrast, GlaxoSmithKline, Mundipharma, Roche, BMJ Journals, MedMedia, AstraZeneca, AbbVie, Lilly, Medahead, Daiichi Sankyo, Sanofi, Merck Sharp & Dohme, Tocagen, Adastr, Gan & Lee Pharmaceuticals, Janssen, Servier, Miltenyi, Boehringer Ingelheim, Telix, Medscape, OncLive. Brendel M: Consultant/Advisory Board: Life Molecular Imaging, GE Healthcare, MIAC; Honoraria: Iba, Life Molecular Imaging, GE Healthcare, Roche. Albert N has received honoraria for lectures, consultation or advisory board participation from Novartis, Advanced Accelerator Applications, Telix Pharmaceuticals, OncLife, Medsir and Servier and research funding from Novocure and Telix Pharmaceuticals. .



Abstract Number: 41

Comparing PET RANO 1.0 with MR RANO for a phase II clinical trial of 18F-DOPA-PET directed dose escalated radiotherapy for glioblastoma

Brinkmann D¹, Pafundi D³, Laack N¹, Kabat B⁴, Hunt C², Lowe V², Kaufmann T², Qian J¹, Vogen D¹, Dooley K⁴, Yan E¹, Sarkaria J¹, Brown P¹, Kizilbash S⁵, Uhm J⁶, Ruff M⁶, Zakhary M⁷, Zhang Y¹, Seaberg M⁸, Wan Chan Tseung H¹, Kemp B², Johnson D², Breen W¹

¹Mayo Clinic Department of Radiation Oncology, Rochester, United States, ²Mayo Clinic Department of Radiology, Rochester, United States, ³Mayo Clinic Department of Radiation Oncology, Jacksonville, United States, ⁴Mayo Clinic Quantitative Health Sciences, Rochester, United States, ⁵Mayo Clinic Department of Medical Oncology, Rochester, United States, ⁶Mayo Clinic Department of Neurology, Rochester, United States, ⁷University of Maryland School of Medicine Department of Radiation Oncology, Baltimore, United States, ⁸UCSF Department of Radiation Oncology, San Francisco, United States

Background and Methods

A phase II clinical trial utilizing 18F-DOPA-PET-guided dose escalation radiation therapy (DERT) for glioblastoma demonstrated improved PFS in MGMT-unmethylated patients and OS in MGMT-methylated patients compared to historical controls. PET RANO 1.0 criteria were recently published together with a call for comparisons with MR RANO 2.0. This secondary analysis of 68 evaluable patients with follow-up amino acid (AA)-PET imaging sought to compare concordance and discordance between progression timepoints per PET RANO 1.0 vs. MR RANO 2.0 criteria in the setting of AA-PET-guided DERT.

Results

Following DERT to 76 Gy, AA-PET images were acquired at each clinically indicated MR surveillance timepoint with median frequency of 1.8 months (range 0.6-5.0 months). PET RANO 1.0 timepoints were concordant and discordant with MR RANO 2.0 timepoints 24% and 76% of the time, respectively, with PET RANO 1.0 occurring earlier in 62% of discordant cases. While there was no statistically significant difference in pre-RT AA-PET volumes between concordant and discordant cohorts, the PET RANO 1.0 progression timepoint was driven primarily by volume change and new lesion criteria. For discordant cases, the median (range) time between the PET and MR progression timepoint was 123 (15-767) days when PET timepoint was earlier and 62 (14-384) days when MR timepoint was earlier. Concordant cases had a much shorter median MR PFS than discordant cases: 3.9 months (95% CI: 3.3-6.5) vs 7.1 months (95% CI: 5.7-8.9), with a logrank p-value of 0.0006. The correlation of PET RANO 1.0 vs MR RANO 2.0 timepoint with OS was 0.5 (p<0.001) vs. 0.4 (p=0.001) respectively, per Spearman correlation coefficient.

Conclusions

These findings indicate that PET RANO 1.0 has a slightly stronger correlation with OS than MR RANO 2.0 for AA-PET-guided DERT, although the correlation is moderate. The frequency of discordant findings suggests benefit of incorporating AA-PET into glioblastoma surveillance.



Abstract Number: 42

Abstract Title: Treatment challenges of primary CNS neuroendocrine tumors and the value of peptide receptor radionuclide therapy: A case report.

Özdemir Z¹, Warnke P^{1,2}, Vorona E³, Roll W⁴, Stummer W¹, Mütter M¹

¹Department of Neurosurgery, University Hospital Münster, Münster, Germany, ²Institute of Anatomy, Technische Universität Dresden, Dresden, Germany, ³Division of Endocrinology, Diabetology and Nutritional Medicine, Department of Internal Medicine, University Hospital Münster, Münster, Germany, ⁴Department of Nuclear Medicine, University Hospital Münster, Münster, Germany

Background

Neuroendocrine tumors (NET) rarely originate in the central nervous system (CNS). Accordingly, diagnostic work up and therapeutic management are challenging. Here, we present a case of a primary CNS NET and report the use of peptide receptor radionuclide therapy (PRRT) in a progressive disease setting.

Methods

This case is reported with respect to the CARE Guidelines: Consensus-based Clinical Case Reporting Guideline.

Results

A 58-year-old male presented with refractory headache. MRI revealed a posterior fossa tumor accompanied by hydrocephalus. After subtotal resection pathology was consistent with a NET with a Ki67 index of 25%. Additional DNA methylation analysis demonstrated epigenetic similarities to medulloblastoma. Staging excluded extracranial metastases, supporting the rare diagnosis of primary CNS NET. Spinal imaging revealed leptomeningeal spread. Multimodal treatment over more than eight years including multiple cytoreductive resections, radiotherapy, somatostatin analogs (SSA) and temozolomide only resulted in short periods of remission. The patient is currently undergoing peptide receptor radionuclide therapy (PRRT) targeting the somatostatin receptor, a treatment well established in non-CNS NET. After two cycles of PRRT with ¹⁷⁷Lu-DOTATATE in a three-month interval, six months after initiation of the first cycle, the patient presented with stable disease in interim staging and decreasing serum chromogranin A levels. Follow-up after completion of planned four cycles of PRRT with ¹⁷⁷Lu-DOTATATE is currently pending.

Conclusion

Management guidelines for primary CNS NET are lacking. Even greater challenges arise in progressive disease settings. Main treatment strategies include maximal safe resection, radiotherapy and systemic options mostly adapted from non-CNS NET. Using the case presented, we discuss the potential role of PRRT in the treatment of CNS NETs.



Abstract Number: 43

Abstract Title: Locoregional distribution of [18F]-FET PET hypermetabolic foci in diffuse lower-grade insular glioma: a potential link to cancer neuroscience

Özdemir Z¹, Roll W², Stummer W¹, Mütter M¹

¹Department of Neurosurgery, University Hospital Münster, Münster, Germany, ²Department of Nuclear Medicine, University Hospital Münster, Münster, Germany

Background

Insular gliomas pose great challenges to maximal safe resection. Perioperative morbidity is comparably high due to adjacent functional structures and vascular anatomy. Synaptic density in limbic/ paralimbic structures, including the insula, is known to be high. According to current concepts of cancer neuroscience, functional connectivity may drive tumor proliferation. Conversely, glioma increase neuronal excitability. This study investigates [18F]-FET PET hypermetabolic foci distribution in insular gliomas to explore a potential link between cancer neuroscience and metabolic heterogeneity.

Materials and Methods

A monocentric retrospective analysis identifies patients with preoperative [18F]-FET PET, that were later diagnosed with diffuse lower-grade glioma (DLGG). Fisher's exact test is performed to compare insular glioma with other DLGG regarding location of hypermetabolic foci (background SUV_{mean} x1.6). Insular gliomas are categorized according to Yasargil's classification for limbic/ paralimbic tumors.

Results

Thirty-five (100%) patients with insular glioma, comprising 5 patients (14%) with tumors restricted to the insula exclusively, 20 patients (57%) with tumors extending to adjacent paralimbic structures (Yasargil type 5A), and 7 patients (20%) with tumors extending to limbic structures (Type 5B), were included. There was no significant difference in the prevalence of [18F]-FET hypermetabolic foci between insular gliomas and other DLGG ($p = 0.63$), with foci identified in 75% of insular gliomas versus 78% in other DLGG. Of all insular gliomas, 19% exhibited [18F]-FET hypermetabolic foci within the insula. In type 5A and 5B tumors, hotspots were predominantly located in paralimbic (52%) and limbic (28%) regions. There was no significant correlation of tumor heterogeneity and locoregional distribution within the group of insular gliomas.

Conclusion

This data demonstrates high intratumoral heterogeneity in the group of insular glioma. However, theoretical high synaptic density in this particular anatomical region does not translate into of [18F]-FET hypermetabolic foci distribution. An ongoing study evaluates locoregional distribution of hypermetabolic foci in lobar DLGG.



Abstract Number: 44

Abstract Title: Application of the PET RANO BM 1.0 criteria in brain metastases: retrospective single center experience

Authors:

Wiegand L¹, Müller K², Mair M^{1,5}, Barci E¹, von Baumgarten L³, Harter P⁴, Brendel M¹, Preusser M⁵, Forbrig R⁶, Greve T³, Schönecker S⁷, Albert N¹

¹Department of Nuclear Medicine, LMU University Hospital, Munich, Germany, ²Department of Neurology, LMU University Hospital, Munich, Germany, ³Department of Neurosurgery, LMU University Hospital, Munich, Germany, ⁴Center for Neuropathology and Prion Research, LMU University Hospital, Munich, Germany, ⁵Division of Oncology, Department of Medicine I, Medical University of Vienna, Vienna, Austria, ⁶Department of Neuroradiology, LMU University Hospital, Munich, Germany, ⁷Department of Radiotherapy and Radiation Oncology, LMU University Hospital, Munich, Germany

Background

The new PET RANO BM 1.0 criteria offer a standardized framework for response assessment in brain metastases using amino acid PET, whereas clinical practice and trials have predominantly relied on MRI. This study applies the new criteria to longitudinal [¹⁸F]FET PET data, analyzing baseline characteristics, response categories, and parameter changes over time.

Methods

In this retrospective, single-center study, patients with brain metastases who had both a baseline and at least one follow-up [¹⁸F]FET PET scan were identified. PET analyses were performed according to the PET RANO BM 1.0 criteria and included the assessment of maximal and mean target-to-background ratios (TBRmax, TBRmean), PET volume, changes of these values between scans, and the presence of either measurable or no / non-measurable disease. Follow-up scans were classified as PET-based progressive disease (PET-PD), stable disease (PET-SD), partial response (PET-PR), or complete response (PET-CR) based on the PET RANO 1.0 BM criteria.

Results

243 scans of 100 patients were evaluated over 105 treatment lines. Measurable disease was present in 75/105 (71%) of baseline scans, and 42% of patients had more than one lesion at baseline. PET-PD was found in 50% of cases, 23% had PET-SD, 24% PET-PR and 3% PET-CR. The vast majority of PET-PD responses were based on significant volume changes and/or new lesions (98%), with only 2% being determined by increased uptake intensity alone. PET-PR was primarily determined by volume reductions (84%). Lung metastases showed a PET-PD rate of 56%, compared to 33% for breast cancer and 46% for melanoma.

Conclusion

Volume changes seem to be the primary determinant of treatment response according to PET RANO BM 1.0, often alongside uptake intensity changes. Response rates also varied depending on origin of metastasis. Future studies should correlate PET RANO 1.0 BM findings with MRI-based RANO 2.0 criteria as well as clinical outcomes.

Author disclosure: Mair, Maximilian J.; Research funding from Bristol-Myers Squibb and travel support from Pierre Fabre; Brendel, Matthias; Consultant/Advisory Board: Life Molecular Imaging, GE Healthcare, MIAC; Honoraria: Life Molecular Imaging, GE Healthcare, Roche; Preusser, Matthias; F. Consultant/Advisory Board;



Nuclear Medicine and Neurooncology (NMN)

NMN Symposium: Precision Medicine

09 - 10. May 2025 / Vienna, Austria

Palais Ferstel

Modest; Bayer, Bristol-Myers Squibb, Novartis, Gerson Lehrman Group (GLG), CMC Contrast, GlaxoSmithKline, Mundipharma, Roche, BMJ Journals, MedMedia, Astra Zeneca, AbbVie, Lilly, Medahead, Daiichi Sankyo, Sanofi, Merck Sharp & Dome, Tocagen, Adastr, Gan & Lee Pharmaceuticals, Servier, Miltenyi, Telix Pharmaceuticals, Böhlinger-Ingelheim, Medscape; Albert, Nathalie L.; B. Research Grant (principal investigator, collaborator or consultant and pending grants as well as grants already received); Modest; Novocure. F. Consultant/Advisory Board; Modest; Novartis/Advanced Accelerator Applications, Telix Pharmaceuticals, Servier.



Abstract Number: 45

Abstract Title: Combined Multiparametric MRI and 18F-FDOPA PET Imaging Features Strongly Predict Molecular Status, Malignant Transformation, and Survival in Gliomas

Ellingson B¹, Yao J, Sanvito F, Raymond C, Lai A, Nghiemphu P, Liao L, Salamon N, Czernin J, Cloughesy T

¹University Of California Los Angeles, Los Angeles, United States

Background

The integration of molecular markers into glioma classification has highlighted the importance of non-invasive imaging biomarkers for diagnosis, prognosis, and response assessment in human gliomas. This study comprehensively summarizes decades of studies from UCLA regarding the predictive value of multiparametric MRI combined with 18F-FDOPA PET imaging for predicting molecular status, malignant transformation, and estimating survival in patients with gliomas.

Material and Methods

Glioma patients ($n > 250$) who underwent either a single pre-surgical or serial 18F-FDOPA PET and multiparametric MRI were analyzed. Imaging features included static and dynamic changes in contrast enhancement volume, T2/FLAIR hyperintense volume, apparent diffusion coefficient (ADC) values, relative cerebral blood volume (rCBV), and 18F-FDOPA PET uptake. Machine learning approaches including clustering analysis and support vector machines were also used to classify molecular status and predict survival outcomes.

Results

18F-FDOPA uptake showed significant positive correlation with Ki-67 proliferation index ($r = 0.72$, $p < 0.001$) and inverse correlation with ADC values in enhancing tumor ($r = -0.64$, $p < 0.001$). IDH wild-type gliomas showed significantly higher 18F-FDOPA uptake (T/N SUVmax > 1.8 , sensitivity 85%, specificity 78%) and rCBV compared with IDH mutant tumors. Machine learning combining MRI and PET imaging features achieved 84% accuracy in predicting IDH status. A general linear model integrating age, treatment, and rate of change in 18F-FDOPA uptake predicted malignant transformation in IDH mutant gliomas with 87% sensitivity and 67% specificity.

Conclusion

The combination of multiparametric MRI and 18F-FDOPA PET imaging provides robust prediction of molecular status, treatment response, and survival in human gliomas. Specifically, 18F-FDOPA metabolic patterns and residual hypermetabolic volume serve as independent prognostic biomarkers that complement conventional imaging features. These findings suggest potential clinical utility for treatment planning and risk stratification.



Abstract Number: 46

Abstract Title: A single arm monocentric phase II study to evaluate safety, tolerability, and preliminary efficacy of carrier-added 4-L-[¹³¹I]iodo-phenylalanine (131I-IPA), administered as sequential injections in patients with recurrent GBM concomitantly to 2nd line external radiation therapy-IPAX – Linz

Authors:

Leibetseder A^{1,2}, Höllmüller I¹, Dierneder J³, Pichler R⁴, Osipova O⁴, Wimmer S⁵, Feichtinger J⁶, Weis S^{7,8}, **Pichler J¹**

¹Department of Internal Medicine and Neurooncology, Neuromed Campus, Kepler University Hospital, Linz, Austria, Linz, Austria, ²Universitätsklinik für Neurologie, Neuromed Campus, Kepler University Hospital, Johannes Kepler University Linz, Linz, Austria, Linz, Austria, ³Department of Nuclear Medicine and Endocrinology, Ordensklinikum Linz Barmherzige Schwestern, , Linz, Austria, Linz, Austria, ⁴Department of Nuclear Medicine, Neuromed Campus, Kepler University Hospital, Linz, Austria, Linz, Austria, ⁵Department of Neuroradiology, Neuromed Campus, Kepler University Hospital, Linz, Austria, Linz, Austria, ⁶Division of Radiooncology, Ordensklinikum Linz Barmherzige Schwestern, Linz, Austria, Linz, Austria, ⁷Division of Neuropathology, Department of Pathology and Molecular Pathology, Neuromed Campus, Kepler University Hospital, Johannes Kepler University Linz, Linz, Austria, Linz, Austria, ⁸Clinical Research Institute for Neuroscience, Neuromed Campus, Johannes Kepler University, Linz, Austria, Linz, Austria

Background

Theranostic is an evolving field in oncology. To enhance outcome combined treatments in relapsed GBM will be the best approach. We conducted a single arm monocentric study to evaluate safety, tolerability, and preliminary efficacy of carrier-added 4-L-[¹³¹I]iodo-phenylalanine (131I-IPA), administered as sequential injections in patients with recurrent GBM concomitantly to 2nd line external radiation therapy - IPAX Linz.

Materials and Methods

8 patients were included. Patients were dosed intravenously 131I-IPA sequentially before and after 2nd line external radiation therapy. Radiotherapy treatment was applied with 30 Gy in 5 fractions for low volumes and 36 Gy in 18 fractions for larger tumors. Inclusion criteria comprised patients with GBM with current evidence for recurrence after standard therapy, interval since end of first line XRT ≥ 6 months, 18F-FET-PET indicating pathologically increased amino acid uptake. Surgery for relapsed tumor was allowed. The primary outcomes were to assess the safety and tolerability; secondary endpoints comprised progression free survival and overall survival.

Results

Included patients represent a younger cohort (mean age 55.7 years) with a quite long progression free survival after first line therapy (mean 16.0 months). We included 5 patients with MGMT unmethylated tumors. Treatment was very well tolerated with no serious adverse event, 3 patients experienced an adverse event which was graduated as possible related (1 leucopenia grade 2, 1 lymphopenia grade 3, 1 thrombocytopenia grade 3, 1 fatigue grade 2). mPFS from relapse to next progression was 3.8 months (2.8 – 6.4 months). mOS was 12.4 months and mOS from 1. diagnosis was 32.2 months.

Conclusion

This expansion cohort with a higher dose of 131I-IPA than in the previous IPAX 1 study showed good tolerability with no relevant systemic toxicity and confirmed the first preliminary efficacy results of the IPAX 1 study.



Nuclear Medicine and Neurooncology (NMN)

NMN Symposium: Precision Medicine

09 - 10. May 2025 / Vienna, Austria

Palais Ferstel

Author disclosure: Leibetseder A. got honorary for ad Board from TELIX Pharmaceuticals, Pichler J. got honorary and grant support from TELIX Pharmaceuticals.



Abstract Number: 47

Abstract Title: Targeting low-density-lipoprotein-receptors in newly diagnosed or recurrent glioblastoma patients: A Phase I exploratory study and potential for theranostics

Authors

Delpassand E¹, Tworowska I¹, Singh P⁵, Pudevalli V⁴, Shafie A², Siddiqui K², Esfandiari R², Flores L¹, Malicet C³, Lecorche P³, Temsamani J³

¹Radiomedix, Houston, United States, ²Excel Diagnostics and Nuclear Oncology, Houston, United States, ³Vect-Horus, Marseille, France, ⁴MDAnderson Cancer Center, Houston, United States, ⁵Ohio State University, Columbus, United States

Background

The overexpression of low-density lipoprotein receptors (LDLR) has been observed in several solid tumors, including GBM. LDLR is expressed at the BBB and facilitates targeted delivery of radiopharmaceuticals to GBM. Here, we present initial findings from the eIND studies of a new probe, ⁶⁸Ga-RMX-VH, targeting LDLR in GBM patients.

Methods

We initiated an open-label, single-dose, eIND-study (#155880) using ⁶⁸Ga-RMX-VH PET/CT in newly diagnosed or recurrent patients with GBM. The primary objective was the assessment of biodistribution and dosimetry of ⁶⁸Ga-RMX-VH. The secondary objective was to correlate the extent of glioblastoma multiforme (GBM) visualized on contrast-enhanced brain MRI with the distribution of ⁶⁸Ga-RMX-VH PET/CT within the brain of each subject. A total of 10 GBM subjects have been scheduled to be enrolled, with 5 of them enrolled in the dosimetry group.

Results

We enrolled 4 GBM patients (3 males, 1 female, 58-68 y.o) who underwent craniotomy, adjuvant chemotherapy, and/or XRT and showed disease progression on MRI/CT scans. Pathology reported GBM with MGMT-promoter-methylation, IDH-Wild-Type and EGFR-mutated (Ki-67=25-60%). PET/CT scan of ⁶⁸Ga-RMX-VH showed satisfactory targeting along the resection and corresponded to contrast-enhanced regions on the MRI. The SUV max was 1.1-2.1. The blood SUV mean was 2.35±0.4 (20min) reduced to 0.7±0.1(180 minutes). The SUV mean of the liver and spleen were 2.25±0.1 and 1.95±0.1(20minutes) reduced to 0.9±0.4 and 0.4±0.1(180min). Activity was cleared through the kidneys and bladder at early time points.

Conclusions

⁶⁸Ga-RMX-VH can successfully target LDLR-over-expressing GBM. The radiotracer uptake correlates with enhanced and flair areas on the brain MRI. If successful, the agent can serve as a diagnostic probe for selecting and stratifying GBM patients for targeted alpha therapy.

Author disclosure: Ebrahim S Delpassand: RadioMedix-co-founder.



Abstract Number: 48

Abstract Title: IPAX-2: Phase 1 safety and dose finding study of [¹³¹I]IPA plus standard of care in patients with newly diagnosed glioblastoma

Authors:

Pichler J¹, Singhal N², Gan H³, Braat A⁴, Pullin W⁵, Cerqueira B⁶

¹Department of Internal Medicine and Neuro-oncology, Kepler University Hospital, Johannes Kepler University, Linz, Austria, ²Royal Adelaide, Adelaide, Australia, ³Cancer Clinical Trials Centre, Austin Health, Heidelberg, Australia, ⁴UMC Utrecht, Utrecht, The Netherlands, ⁵Gold Coast University Hospital, Southport, Australia, ⁶Telix Pharmaceuticals, Melbourne, Australia

Background

Glioblastoma (GBM) overexpresses L-type amino transporter (LAT) 1 and 2, which are the target 4-L-[¹³¹I] iodo-phenylalanine ([¹³¹I]IPA). Previous studies of [¹²³I]IPA as a SPECT tracer showed retention in glioma tissue, high metabolic stability, and uptake by >85% of gliomas. Results from a phase 1 trial (IPAX-1) that explored [¹³¹I]IPA + radiotherapy in patients with recurrent GBM demonstrated a favorable safety profile and promising efficacy. The objective of IPAX-2 (NCT05450744) is to evaluate the safety and tolerability of [¹³¹I]IPA in patients newly diagnosed with GBM.

Materials and Methods

IPAX-2 is a phase 1, multicenter, open-label, single-arm, parallel-group, dose-finding study to evaluate the safety of ascending radioactive dose levels of [¹³¹I]IPA + best standard of care in newly diagnosed patients with GBM. Eligible patients (N=12) will be aged 18-65 years with histologically-confirmed intracranial GBM following surgical resection; no prior systemic therapy or radiation for GBM; a Karnofsky Performance Status ≥70; a plan to begin chemoradiation 3-6 weeks after surgical resection with Stupp regimen; adequate organ function; and adequate tissue samples previously archived. Four cohorts will encompass a 3+3 dose escalation, beginning at 2 doses of 3 GBq each. Dose 1 will be administered prior to external beam radiation therapy (EBRT), and Dose 2 will be administered following completion of EBRT. ¹⁸F-FET PET will be used to identify suitable candidates with LAT1/2 overexpression, establish a baseline, and provide quantitative follow-up information. Primary outcome measures are 1) the incidence rate and severity of dose-limiting toxicities, and 2) the safety, tolerability, and recommended phase 2 dose.

Results

This study is currently enrolling; no results are available at the time of abstract submission.

Conclusion

[¹³¹I]IPA unique characteristics, including its specific and sustained tumor accumulation and intrinsic cytostatic and radiosensitizing effect, make it an attractive therapeutic probe against GBM.

Disclosures

Sponsored by Telix Pharmaceuticals.

Author disclosure: Gan, Hui; AbbVie; previous consultancy roles and/or research support; Cerqueira, Brenda; Telix Pharmaceuticals; employment



Abstract Number: 49

Abstract Title: Indigenously synthesized one vial kit Tc-99m HYNICTATE DOTATATE a low cost alternative to Ga-68 DOTATATE for primary and recurrent meningiomas

Authors:

Amjad H¹, Raza M², Khawar A¹

¹Pakistan Institute Of Engineering And Applied Sciences, Islamabad, Pakistan, ²Nuclear Medicine Centre, AFIP, Rawalpindi, Pakistan

Background

Presence of Somatostatin receptors type 2 (SSTR-2) on brain tumors like meningioma and glioma is being envisioned as new avenue of theranostic use of Ga-68 DOTATATE/ Lu-177 DOTATATE for imaging and therapy of recurrent/ inoperable meningioma. Tc-99m HYNICTATE SPECT/CT is seen as low cost alternative to Ga-68 DOTATATE PET/CT for imaging SSTR positive tumors. Current study aims at evaluation of TC-99m HYNICTATE single vial kit indigenously synthesized at IPD, PINSTECH in primary and recurrent meningioma

Material and Methods

This is an ongoing study being carried out in NMC, AFIP, Rawalpindi. Patients presenting in Neurooncology department of CMH, Rawalpindi with neurological symptoms and MRI findings suggestive of meningioma / residual or recurrent meningioma are included. All patients underwent Tc-99m HYNICTATE SPECT/CT with dual head Gamma Camear after being injected with 20 mCi of Tc-99m HYNICTATE single vial kit. The uptake of Tc-99m HYNICTATE in primary and recurrent meningioma is analyzed.

Results

Up till now 6 male patients mean age of 62.5 years 4 with suspicion of primary meningioma (smallest 1.5 × 1.3 cm and largest 5.1 × 7.6 × 5.5 cm) , 01 with suspicion of Schwannoma/ meningioma and one with recurrent meningioma have been analyzed. Among 4 primary meningioma patients one had H/P of grade II meningothelial meningioma, one was at cerebellopontine angle with high uptake and other had no uptake. The patient with Schwannoma/ meningioma also showed moderate to high uptake. Patient with recurrent meningioma (grade II atypical meningioma) showed high uptake.

Discussion

Tc-99m HYNINTATE showed varied absent to moderate uptake in primary meningioma. The absent uptake was probably due to low grade or small size of tumor. The scan ruled out invasion of bone in cerebellopontine angle meningioma. H/P for final diagnosis of schwannoma/meningioma is awaited.

Conclusion

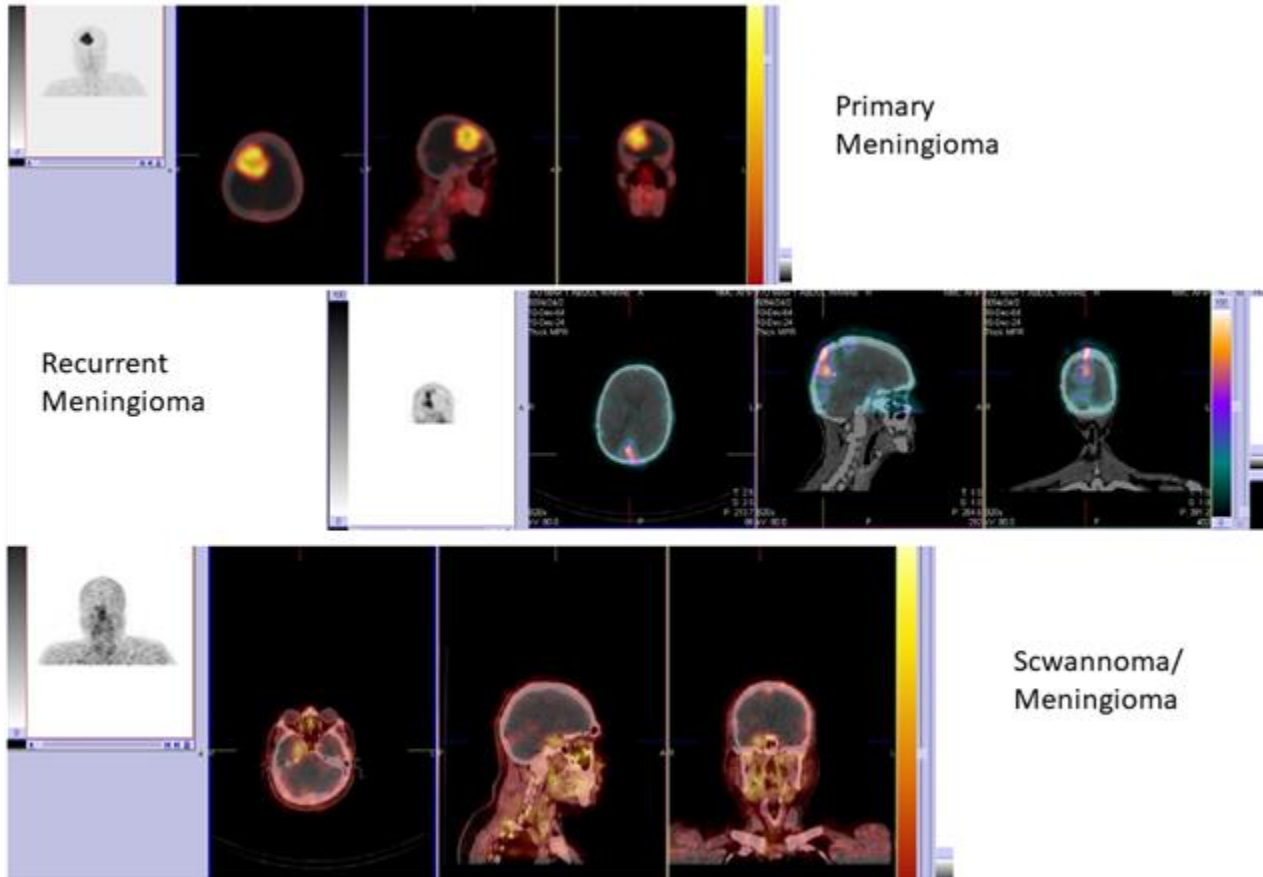
Tc-99m HYNICTATE can effectively delineate primary and recurrent meningiomas.



NMN Symposium: Precision Medicine

09 - 10. May 2025 / Vienna, Austria

Palais Ferstel





Abstract Number: 50

Abstract Title: Rare Primary Intracranial Histiocytic Sarcoma in a Pediatric Case

Authors:

Aslan E¹, Güreşçi S², Aslan S⁴, Demirci H³, Gülaldı N¹

¹University of Health Sciences, Department of Nuclear Medicine, Ankara Bilkent City Hospital, Ankara, Turkey,

²University of Health Sciences, Department of Pathology, Ankara Bilkent City Hospital, Ankara, Turkey, ³Ankara

Yıldırım Beyazıt University, Department of Neurosurgery, Ankara Bilkent City Hospital, Ankara, Turkey, ⁴Halil Şıvgın Çubuk State Hospital, Department of Neurosurgery, Ankara, Turkey

Background

Intracranial histiocytic sarcoma(IHS) is an exceedingly rare and aggressive neoplasm that arises from histiocytes, which are immune cells derived from the monocyte-macrophage lineage. In children, the disease is even more enigmatic, with limited case reports and studies available to guide management.

Case Description

We present a child with a multifocal primary IHS involving the cerebral hemispheres. A 3-year-old boy suffered from nausea and epileptic seizures. The neurological examination was normal following a seizure. His previous medical history included another epileptic seizure at 3 months of age and macrocephaly.

CT revealed a 13x8 cm lobed mass on both the parietal and occipital lobes. Peripheral edema was detected, and the intracranial mass compressed the posterior horns of both lateral ventricles. Contrast-enhanced MRI revealed a 123x80x81mm large, heterogeneous lesion of a large mass that has features of both solid and cystic components, with the solid regions showing heterogeneous contrast-enhancement (Fig 1A).

The patient underwent neurosurgical surgery. Immunohistochemistry showed that the cells, including the large bizarre cells, were positive for CD68,CD163 suggesting their histiocytic nature. The cells were negative for GFAP, excluding the possibility of glioblastoma. The diagnosis was histiocytic sarcoma.

F18-FDG PET/CT was carried out for staging. Apart from the brain, there was no evidence of lymphoma involvement (Fig 1B). The huge mass was hypermetabolic and correlated with the high mitotic index of this tumor, which was 80-85%. The patient has been alive for 5 months.

Conclusion

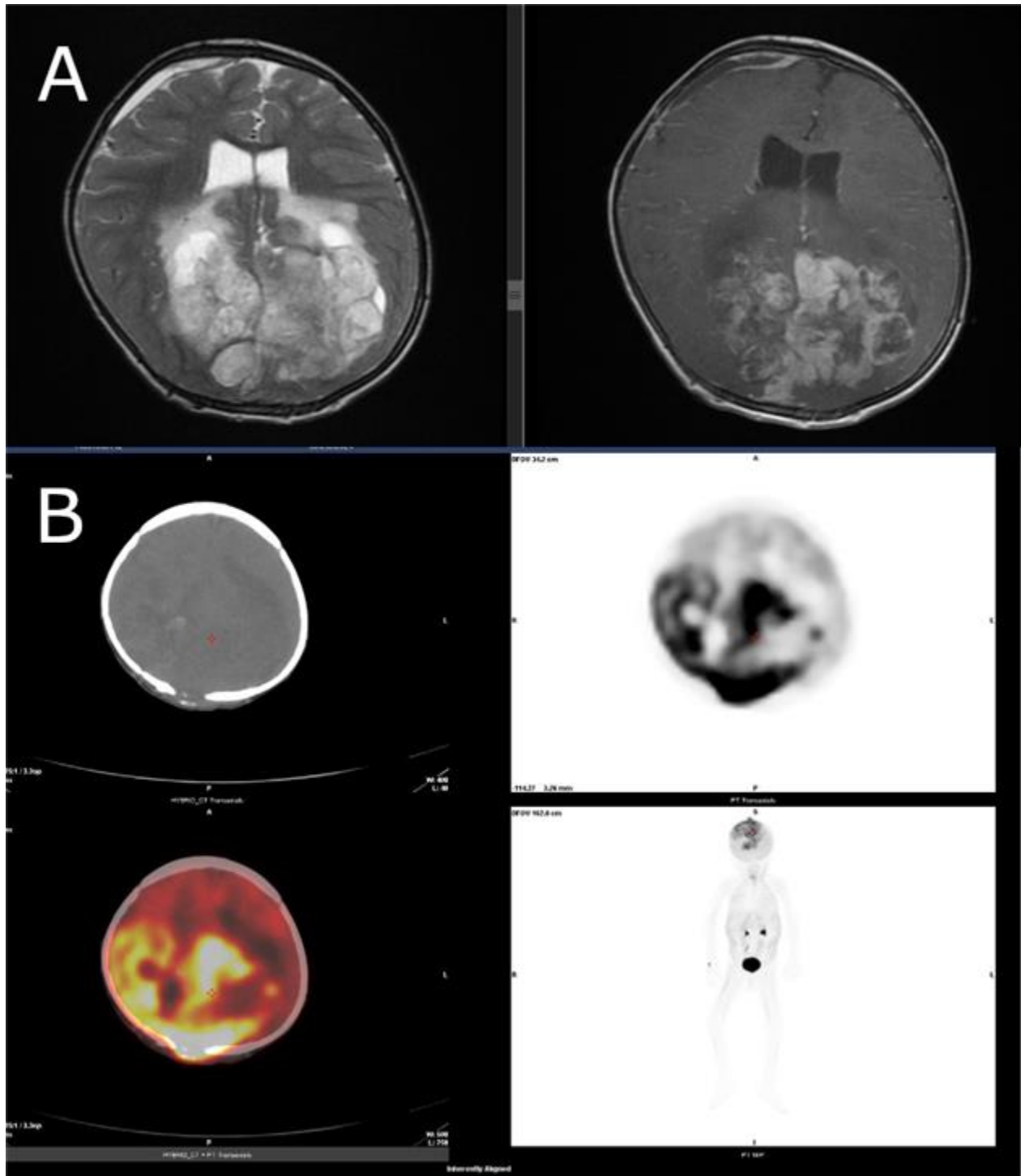
Primary IHS is a rare neoplasm, especially in childhood. While CT and MRI show anatomical properties of the lesion, F18-FDG PET/CT imaging plays an important role in the staging and treatment follow-up of these patients. The high metabolic activity uptake of the tumour on PET/CT imaging may lead to closer follow-up and intensive chemoradiotherapy regimen as it increases the possibility of intra-tumor heterogeneity and aggressiveness.



**NMN Symposium:
Precision Medicine**

09 - 10. May 2025 / Vienna, Austria

Palais Ferstel





Abstract Number: 51

Abstract Title: Measurable disease for response assessment in IDH-mutant glioma – a comparison of MRI-based (RANO 2.0) versus PET-based (PET RANO 1.0) assessment

Authors:

Barci E¹, Reis J², Mair M^{1,3}, Isakaj J¹, Müller K⁴, Kaiser L¹, Preusser M³, Harter P^{5,6}, von Baumgarten L^{5,7}, Thon N⁸, Forbrig R², Albert N¹

¹Department Of Nuclear Medicine, LMU University Hospital, Lmu Munich, Germany, , , ²Institute of Neuroradiology, LMU University Hospital, LMU Munich, Germany, , , ³Division of Oncology, Department of Medicine I, Medical University of Vienna, Vienna, Austria, , , ⁴Department of Neurology, LMU University Hospital, LMU Munich, Germany, , , ⁵German Cancer Consortium (DKTK), partner site Munich, a partnership between DKFZ and University / University Hospital, LMU Munich, Germany, , , ⁶Center for Neuropathology and Prion Research, Faculty of Medicine, LMU Munich, Germany, , , ⁷Department of Neurosurgery, LMU University Hospital, LMU Munich, Germany, , , ⁸Department of Neurosurgery, University Hospital of the Ruhr-University of Bochum, Germany

Purpose

In clinical trials for patients with IDH-mutant glioma, "measurable disease" on MRI is a key inclusion criterion and baseline for response assessment. Recently, amino acid PET-based criteria have been proposed for response assessment in clinical trials (PET RANO 1.0 criteria). We aimed to compare "measurable disease" using MRI-based RANO 2.0 and PET RANO 1.0 criteria in patients with IDH-mutant glioma.

Methods

In this retrospective single-center study, patients with newly diagnosed IDH-mutant gliomas with available [18F]FET PET and MRI either preoperatively before biopsy or resection or postoperatively within a maximum of 12 months after resection, were identified. Analysis was performed by two independent investigators to assess "measurable disease" according to MRI-based RANO 2.0 and PET-based PET RANO 1.0 criteria, and lesion size, uptake intensity (maximal and mean target-to-background ratio: TBRmax, TBRmean) and PET volume were assessed.

Results

A total of 212 patients (median age 47 years, range 24–90; 44.8% female) were analyzed, including 148 preoperative (median time between PET and surgery: 0.3 months, range 0.0 – 6.8) and 64 postoperative cases (median time between surgery and PET: 2.1 months, range 0.2 - 11.7). Overall, patients had more often measurable disease on PET compared to MRI (61.3% vs. 49.1%, p=0.015). Preoperatively, MRI and PET identified similar rates of measurable disease (60.8% vs. 59.5%, p>0.5), while PET identified a higher number of postoperative cases with measurable disease than MRI (65.6% vs. 21.9%, p<0.001). While MRI showed a similar rate of measurable disease in oligodendroglioma and astrocytoma (50% vs. 48.2%; p>0.05), PET revealed a higher rate in oligodendroglioma compared to astrocytoma (79% vs. 45.5%; p<0.01).

Conclusion

Amino acid PET detects measurable disease more frequently than MRI, particularly in oligodendrogliomas and postoperative settings. These findings support the use of PET-based evaluation of disease burden in IDH-mutant glioma as an inclusion criterion for clinical trials.



Nuclear Medicine and Neurooncology (NMN)

NMN Symposium: Precision Medicine

09 - 10. May 2025 / Vienna, Austria

Palais Ferstel

Author Disclosure: Maximilian Mair has received research funding from Bristol-Myers Squibb and travel support from Pierre Fabre.



Abstract Number: 52

Abstract Title: Predicting the added value of [¹⁸F]FET PET in glioblastoma patients using MRI radiomics

Authors:

Kaiser L¹, Zounek A¹, Istrefi E¹, Isakaj J¹, Barci E¹, Reis J², Forbig R², Wiestler B³, Müller K⁴, von Baumgarten L^{5,6}, Mair M^{1,7}, Ziegler S^{1,8}, Albert N¹

¹Department of Nuclear Medicine, LMU University Hospital, LMU Munich, Germany, Munich, Germany, ²Institute of Neuroradiology, LMU University Hospital, LMU Munich, Germany, Munich, Germany, ³Department of Neuroradiology, Klinikum Rechts der Isar, Technical University of Munich, Germany, Munich, Germany, ⁴Department of Neurology, LMU University Hospital, LMU Munich, Germany, Munich, Germany, ⁵German Cancer Consortium (DKTK), partner site Munich, a partnership between DKFZ and University / University Hospital, LMU Munich, Germany, Munich, Germany, ⁶Department of Neurosurgery, LMU University Hospital, LMU Munich, Germany, Munich, Germany, ⁷Division of Oncology, Department of Medicine I, Medical University of Vienna, Vienna, Austria, Munich, Germany, ⁸Department of Nuclear Medicine, Hannover Medical School (MHH), Hannover, Germany, Munich, Germany

Background

MRI is the standard imaging modality for patients with glioblastoma, and contrast-enhancing volumes are typically used as target for treatment planning. However, MRI may underestimate tumor extent, and [¹⁸F]FET PET can help to depict tumor extent beyond contrast-enhancing volumes, which is found in a considerable proportion of cases. This study investigates whether MRI-based radiomics can predict if a patient has metabolically active tumor parts outside of the contrast-enhancing volumes on MRI and could therefore benefit from additional [¹⁸F]FET PET scanning.

Material and Methods

A total of 239 patients with preoperative [¹⁸F]FET PET and newly diagnosed glioblastoma were included. The PET volume was segmented using a 1.6-fold background threshold, while the MRI volume, including T2-hyperintensity, was obtained with the BraTS toolkit. Overlapping volumes and the largest Hausdorff distance between [¹⁸F]FET PET and MRI volumes were calculated. Radiomic features were extracted from T1 CE and T2 MRI. Logistic regression with nested cross-validation (5 splits, 50 repetitions) was used to classify whether the [¹⁸F]FET PET volume beyond MRI is >1 ml and has a Hausdorff distance >1 cm.

Results

In 145 (61%) patients, [¹⁸F]FET PET identified a PET volume located outside the MRI volume, whereas in 94 (39%) patients, the [¹⁸F]FET-positive volume was completely within or only minimally exceeded the contrast-enhancing MRI volume. The Dice coefficient was 0.37. Using radiomics, patients with PET volumes located outside of the MRI volume could be identified with an AUC of 0.78 (PPV 0.80; NPV 0.60).

Conclusion

MRI-based radiomics provided moderate accuracy for the identification of glioblastoma patients, who could benefit from an additional [¹⁸F]FET PET by PET volume delineation outside of the MRI volumes. Whether this approach can optimize preoperative planning and therapy monitoring through targeted use of [¹⁸F]FET PET in glioblastoma patients needs to be evaluated in further studies.



Abstract Number: 53

Abstract Title: Can MRI radiomics predict [¹⁸F]FET PET positivity in non-enhancing gliomas?

Authors:

Kaiser L¹, Zounek A¹, Istrefi E¹, Isakaj J¹, Barci E¹, Reis J², Forbrig R², Wiestler B³, Müller K⁴, von Baumgarten L^{5,6}, Mair M^{1,7}, Ziegler S^{1,8}, Albert N¹

¹Department of Nuclear Medicine, LMU University Hospital, LMU Munich, Munich, Germany, ²Institute of Neuroradiology, LMU University Hospital, LMU Munich, Munich, Germany, ³Department of Neuroradiology, Klinikum Rechts der Isar, Technical University of Munich, Munich, Germany, ⁴Department of Neurology, LMU University Hospital, LMU Munich, Munich, Germany, ⁵German Cancer Consortium (DKTK), partner site Munich, a partnership between DKFZ and University / Uni-versity Hospital, LMU Munich, Munich, Germany, ⁶Department of Neurosurgery, LMU University Hospital, LMU Munich, Munich, Germany, ⁷Division of Oncology, Department of Medicine I, Medical University of Vienna, Vienna, Vienna, Austria, ⁸Department of Nuclear Medicine, Hannover Medical School (MHH), Hannover, Hannover, Germany

Background

[¹⁸F]FET PET is frequently performed in patients with suspected gliomas without contrast enhancement on MRI to guide tissue sampling by hotspot delineation. However, about one third of non-enhancing gliomas do not show uptake in [¹⁸F]FET PET. As scanner capacities in times of increasing demand for PET imaging are limited, prediction of [¹⁸F]FET positivity would be helpful to avoid unnecessary scanning of patients without valuable PET information. We therefore aimed to investigate whether radiomic features from conventional MRI can predict [¹⁸F]FET positivity in patients with non-enhancing gliomas.

Material and Methods

A total of 282 patients with preoperative [¹⁸F]FET PET and newly diagnosed glioma without contrast enhancement on T1-weighted MRI were included. Tumor volumes on MRI were segmented using the BraTS toolkit, and radiomic features were extracted from contrast-enhanced T1 and T2 sequences. Logistic regression with nested cross-validation (5 splits, 50 repetitions) was applied to predict [¹⁸F]FET positivity, defined as significantly increased uptake (>1.6-fold background).

Results

192 (68%) of non-enhancing gliomas were [¹⁸F]FET-positive, whereas 90 (32%) did not show significantly increased uptake on [¹⁸F]FET PET and were classified as [¹⁸F]FET-negative. The MRI-based radiomics model identified [¹⁸F]FET-positive cases with an AUC of 0.64 (PPV 0.78; NPV 0.45).

Conclusion

In patients with non-enhancing gliomas, MRI-based radiomics demonstrated only a moderate performance in predicting [¹⁸F]FET positivity. Further studies are needed to investigate whether accuracy increases with deep learning-based methods.



Abstract Number: 54

Abstract Title: 18F-FET uptake in the pons in children with a normal brainstem after radiotherapy

Authors:

Susin D¹, Gromova E

¹MIBS, Saint-petersburg, Russian Federation

Background

To interpret correctly the PET-FET in the brain pathology there is a need to know normal FET uptake. The topographic features of pediatric brain tumors draw the attention to the structures of the posterior cranial fossa.

According to our experience there is an abnormal increase of FET uptake in normal children's pons after radiotherapy of tumors in posterior cranial fossa.

The guideline of the EANM recommends choosing unaffected cortex of the hemisphere contralateral to the tumor as a reference region. There is no contralateral brain structure that can be used as a reference for pons, which makes difficult PET images analyses. The aim of the study was to calculate the level of increase of 18F-FET in pons, and select optimal reference region to pons analysis for children after radiotherapy.

Method

For retrospective analysis 28 children (aged 3-16 years) examined by PET-FET were selected. Entry criteria included children with intact pons in MRI after radiotherapy brain tumor. Pons-to-cerebellum ratio and pons-to-frontal cortex ratio were analyzed. For each ratio, six calculation methods were used, depending on the size of the region of interest (ROI) and the SUV statistics (maximum, mean, peak SUV in the 10 mm ROI or mean SUV in the banana-shaped ROI).

Result

As a result of the measurements, SUV values of FET uptake in the brainstem, the cerebellum and in the frontal cortex were received using three methods designated as Maximum, Mean and Peak, and Banana-Mean for frontal cortex.

The FET uptake in the pons was significantly higher than in the frontal cortex, regardless the used measurement method. The FET uptake in pons and cerebellum showed no significant differences PET-FET scans.

Conclusion

The results allow us to recommend the cerebellum as a reference structure in the pons analysis of PET-FET in children with posterior cranial fossa lesions.



Abstract Number: 55

Abstract Title: Identifying residual tumor burden in postoperative glioblastoma: A comparative analysis of MR-based RANO resect classes vs. [18F]FET-PET

Authors:

Blobner J¹, Mueller K², Forbrig R³, von Baumgarten L¹, Tonn J¹, Thon N¹, Harter P⁴, Schoenecker S⁵, Karschnia P⁶, Albert N⁷

¹Department of Neurosurgery, LMU University Hospital, Munich, Germany, ²Department of Neurology, LMU University Hospital, Munich, Germany, ³Institute for Neuroradiology, LMU University Hospital, Munich, Germany, ⁴Center for Neuropathology and Prion Research, LMU University Hospital, Munich, Germany, ⁵Department of Radiation Oncology, LMU University Hospital, Munich, Germany, ⁶Department of Neurosurgery, FAU University Hospital of the Friedrich-Alexander-University, Erlangen, Germany, ⁷Department of Nuclear Medicine, LMU University Hospital, Munich, Germany

Background

Extensive resection improves glioblastoma survival, with residual tumor volume as a key prognostic marker. The RANO resect group proposed a classification based on postoperative MRI volume. With [18F]FET-PET increasingly used for glioma delineation, we compared MRI- and PET-based volumetrics.

Methods

We retrospectively analyzed IDH-wildtype glioblastoma patients who underwent [18F]FET-PET and MRI post-surgery. Two investigators assessed residual tumor volumes using PET RANO 1.0 and MRI-based RANO resect criteria, comparing both modalities. Tumor detection confidence was rated from 0 (no tumor) to 5 (definite tumor).

Results

We identified 46 patients with available MRI and [18F]FET-PET for review. Preliminary analysis of 19 cases showed a median contrast-enhancing (CE+) tumor volume of 0.83 cm³ (range 0–4.17 cm³) on postoperative MRI. Non-contrast-enhancing (CE-) tumor was present in 79% (15/19) with a median volume of 2.79 cm³ (range 0–27.5 cm³). Most cases were classified as RANO resect classes 2 and 3, with 21% (4/19) assigned to class 1. [18F]FET-PET detected suspected residual disease in all patients, with a median PET-positive volume of 13.45 cm³ (range 1.26–48.80 cm³) and a median TBRmax of 2.97 (range 2.07–6.12 cm³). PET volumes consistently exceeded MRI-defined volumes with a median overlap of 0.17 cm³ - 5% relative to PET and 65% relative to MRI. PET volumes increased across RANO resect classes, from 14.9 cm³ in class 1 to 21.8 cm³ in class 3. PET raters also reported higher confidence in tumor detection (median 5) compared to MRI investigators (median 4).

Conclusion

Our study suggests that PET may detect more residual disease post-surgery than MRI, with PET volumes often exceeding those delineated by MRI indicating higher sensitivity. [18F]FET-PET may present a valuable tool to complement MRI for the stratification of patients based on the residual tumor volume and potentially also to guide local therapies.



Abstract Number: 56

Abstract Title: CXCR4-targeted PET imaging of central nervous system lymphoma and glioma using [⁶⁸Ga]Ga-Pentixafor

Authors:

Werner J^{1,2}, **Tomasich E**^{1,3}, **Wöhner A**⁴, **Albert N**⁵, **Mayerhoefer M**^{6,7}, **Galldiks N**^{2,8}, **Traub-Weidinger T**^{7,9}, **Hacker M**^{7,9}, **Preusser M**^{1,3}, **Berghoff A**^{1,3}

¹Division of Oncology, Department of Medicine I, Medical University of Vienna, Vienna, Austria, ²Dept. of Neurology, Faculty of Medicine and University Hospital Cologne, University of Cologne, Cologne, Germany, ³Christian Doppler Laboratory for Personalized Immunotherapy, Department of Medicine I, Medical University of Vienna, Vienna, Austria, ⁴Division of Neuropathology and Neurochemistry, Department of Neurology, Medical University of Vienna, Vienna, Austria, ⁵Dept. of Nuclear Medicine, LMU Hospital, LMU Munich, Munich, Germany, ⁶Dept. of Radiology, Memorial Sloan Kettering Cancer Center, New York, USA, ⁷Dept. of Biomedical Imaging and Image-guided Therapy, Medical University of Vienna, Vienna, Austria, ⁸Institute of Neuroscience and Medicine (INM-3), Research Center Juelich, Juelich, Germany, Juelich, Germany, ⁹Division of Nuclear Medicine, Medical University of Vienna, Vienna, Austria

Background

Initial results suggest that PET imaging of the chemokine receptor CXCR4 is of considerable interest for differential diagnosis and theranostics approaches. Here, we summarized findings of CXCR4 PET imaging in an institutional series of lymphoma of the central nervous system (CNSL) and glioma.

Methods

Twenty-three patients with CNSL and 16 patients with glioma (IDH-wildtype, n=9) underwent PET imaging using the CXCR4-directed tracer [⁶⁸Ga]Ga-Pentixafor. In 18 patients, serial PET imaging was performed (range, 2-14 scans), resulting in a total of 104 PET scans. For evaluation, PET scans were classified as [⁶⁸Ga]Ga-Pentixafor-positive and -negative visually, and the maximum standardized uptake value (SUVmax) was obtained from [⁶⁸Ga]Ga-Pentixafor-PET.

Results

Twenty-four of all 39 patients (62%) had at least one [⁶⁸Ga]Ga-Pentixafor-positive PET (CNSL, 57%; glioma, 69%). [⁶⁸Ga]Ga-Pentixafor-positive PET scans were more common in patients with IDH-wildtype gliomas (89%) than in IDH-mutant gliomas (43%). In patients with [⁶⁸Ga]Ga-Pentixafor-positive PET, the average SUVmax was 6.4±4.0 in CNSL, and 3.4±1.0 in gliomas (P=0.155). Besides visualization of tumors, [⁶⁸Ga]Ga-Pentixafor uptake was observed in two patients with radionecrosis. In four CNSL patients who had undergone methotrexate/cytarabine-based first-line therapy, serial PET revealed a significant reduction of SUVmax after chemotherapy completion (average decrease of SUVmax from 4.5±3.8 to 0.6±0.7; P=0.044). In three of those four patients, tumor progression has not been reached (range of time after the follow-up PET, 4-55 months); one patient deceased 44 months after the follow-up PET. In contrast, another patient with an increase in SUVmax from 6.9 to 11.0 after first-line treatment died one month after the follow-up PET.

Discussion

[⁶⁸Ga]Ga-Pentixafor PET seems to be of value for non-invasively visualizing and quantifying CXCR4 receptor binding. In CNSL, changes in [⁶⁸Ga]Ga-Pentixafor uptake following therapy may indicate potential for response assessment. CXCR4-targeting radioligand therapies might be more promising in CNSL than in glioma.



Nuclear Medicine and Neurooncology (NMN)

NMN Symposium: Precision Medicine

09 - 10. May 2025 / Vienna, Austria

Palais Ferstel

Author disclosure. Nathalie L. Albert has received honoraria for lectures, consultation or advisory board participation from Advanced Accelerator Applications, Medsir, Novartis, OncLive, Servier and Telix Pharmaceuticals, and research funding from Novocure and Telix Pharmaceuticals; Norbert Galldiks has received honoraria for lectures from Blue Earth Diagnostics, for advisory board participation from Telix Pharmaceuticals and Servier, and for consultancy services from Telix Pharmaceuticals; Matthias Preusser has received honoraria for lectures, consultation or advisory board participation from the following for-profit companies: Bayer, Bristol-Myers Squibb, Novartis, Gerson Lehrman Group (GLG), CMC Contrast, GlaxoSmithKline, Mundipharma, Roche, BMJ Journals, MedMedia, Astra Zeneca, AbbVie, Lilly, Medahead, Daiichi Sankyo, Sanofi, Merck Sharp & Dome, Tocagen, Adastr, Gan & Lee Pharmaceuticals, Janssen, Servier, Miltenyi, Böhringer-Ingelheim, Telix, Medscape; Anna Sophie Berghoff has research support from Daiichi Sankyo, Roche and honoraria for lectures, consultation or advisory board participation from Roche Bristol-Meyers Squibb, Merck, Daiichi Sankyo, AstraZeneca, CeCaVa, Seagen, Alexion, Servier as well as travel support from Roche, Amgen and AbbVie.



Abstract Number: 57

Abstract Title: Comparative study of measurable disease according to PET RANO 1.0 vs. RANO 2.0 criteria at baseline after radiotherapy and at first progression in glioblastoma

Authors:

Müller K¹, von Polenz I², Reis J³, Wiegand L², Isakaj J², Aras T², Mair M², Barci E², Kaiser L², Schönecker S⁴, Greve T⁵, Harter P⁶, von Baumgarten L⁵, Forbrig R³, Preusser M⁷, Albert N²

¹Department of Neurology, University Hospital Of Munich, LMU, Munich, Germany, ²Department of Nuclear Medicine, University Hospital Of Munich, LMU, Munich, Germany, ³Department of Neuroradiology, University Hospital Of Munich, LMU, Munich, Germany, ⁴Department of Radiation Oncology, University Hospital Of Munich, LMU, Munich, Germany, ⁵Department of Neurosurgery, University Hospital Of Munich, LMU, Munich, Germany, ⁶Center for Neuropathology and Prion Research, LMU, Munich, Germany, ⁷Division of Oncology, Department of Medicine I, Medical University of Vienna, Vienna, Austria

Background

Response assessment in glioblastoma is based on the evaluation of contrast enhancement on MRI using RANO 2.0 criteria. 'Measurable disease' serves as an inclusion criterion for clinical trials both at baseline after radiotherapy and at first recurrence. The recently introduced PET RANO 1.0 criteria integrate amino acid PET into standardized response assessment. Our study compares the frequency of 'measurable disease' according to PET RANO 1.0 with MRI-based RANO 2.0 criteria at common inclusion timepoints for glioblastoma trials.

Methods

This retrospective, single-center study included patients with IDH-wildtype glioblastoma who underwent [¹⁸F]FET-PET and MRI at the RANO 2.0 baseline up to 35 days after completion of radiotherapy or at first recurrence (max. time between scans: 28days). Two independent investigators assessed 'measurable disease' based on PET RANO 1.0 and RANO 2.0 criteria. Lesion size, uptake intensity (TBRmax, TBRmean), and their correlation with Karnofsky performance status (KPS) were evaluated.

Results

A total of 109 patients (median age 58 years, IQR 53-68) were included, 43 at baseline and 66 at first recurrence. Using RANO 2.0, measurable disease was identified in 20/43 cases (46.5%) at baseline and in 43/66 (65.2%) at recurrence (median sum of cross-sectional diameters: 20.1mm, 21.3mm). In contrast, with PET RANO 1.0 a significantly higher proportion of patients showed measurable disease with 39/43 cases (90.7%) at baseline and 65/66 (98.5%) at first recurrence (median volume 12.6cm³, 17.5cm³; p<0.001). Baseline TBRmax showed a significant negative correlation with KPS (p<0.002, r<-0.345).

Conclusion

At baseline and first progression, PET RANO 1.0 criteria identify a significantly higher number of patients with measurable disease compared to standard MRI-based RANO 2.0 criteria. These findings suggest that PET-based assessment may provide a more detailed evaluation of disease burden which might broaden eligibility for glioblastoma trials. Prospective validation is warranted to establish the utility for patient stratification in clinical trials.

Author disclosure: Katharina J. Müller: received grant support by the Friedrich-Baur-Stiftung and DFG (German Research Society). Preusser M has received honoraria for lectures, consultation, or advisory board



Nuclear Medicine and Neurooncology (NMN)

NMN Symposium: Precision Medicine

09 - 10. May 2025 / Vienna, Austria

Palais Ferstel

participation from the following for-profit companies: Bayer, Bristol-Myers Squibb, Novartis, Gerson Lehrman Group (GLG), CMC Contrast, GlaxoSmithKline, Mundipharma, Roche, BMJ Journals, MedMedia, Astra Zeneca, AbbVie, Lilly, Medahead, Daiichi Sankyo, Sanofi, Merck Sharp & Dome, Tocagen, Adastra, Gan & Lee Pharmaceuticals, Servier, Miltenyi, Böhringer-Ingelheim, Telix, Medscape, OncLive. Albert N has received honoraria for lectures, consultation or advisory board participation from Novartis / Advanced Accelerator Applications, Telix Pharmaceuticals, Servier and OncLive and research funding from Novocure and Telix Pharmaceuticals. MM has received research funding from Bristol-Myers Squibb and travel support from Pierre Fabre.



Abstract Number: 58

Abstract Title: Clinical utility of [¹⁸F]FET PET in patients with circumscribed astrocytic glioma

Authors:

Werner J^{1,2,3}, Mair M^{1,2,4}, Wollring M³, Barci E⁴, Stetter I³, Pühr H^{1,2}, Tscherpel C^{5,6}, Stoffels G⁶, Hainfellner J⁷, Berghoff A^{1,2}, Sunder-Plassmann V^{1,2}, Widhalm G⁸, Eckert F⁹, Kasprian G^{10,11}, Nakuz T^{10,12}, Beck A¹³, Harter P^{13,14,15}, von Baumgarten L^{14,15,16,17}, Thon N^{17,18}, Schönecker S¹⁹, Forbrig R²⁰, Mottaghy F^{21,22,23}, Lohmann P^{6,21}, Fink G^{3,6}, Langen K^{6,18,23}, Galldiks N^{3,6,23}, Albert N^{4,15}, Preusser M^{1,2}

¹Division of Oncology, Department of Medicine I, Medical University of Vienna, Vienna, Austria, ²Christian Doppler Laboratory for Personalized Immunotherapy, Department of Medicine I, Medical University of Vienna, Vienna, Austria, ³Dept. of Neurology, Faculty of Medicine and University Hospital Cologne, University of Cologne, Cologne, Germany, ⁴Dept. of Nuclear Medicine, LMU University Hospital, LMU Munich, Munich, Germany, ⁵Dept. of Neurology, University Hospital Frankfurt, Goethe University, Frankfurt am Main, Germany, ⁶Inst. of Neuroscience and Medicine (INM-3, INM-4), Research Center Juelich, Juelich, Germany, ⁷Division of Neuropathology and Neurochemistry, Department of Neurology, Medical University of Vienna, Vienna, Austria, ⁸Dept. of Neurosurgery, Medical University of Vienna, Vienna, Austria, ⁹Dept. of Radiation Oncology, Comprehensive Cancer Center Vienna, Medical University of Vienna, Vienna, Austria, ¹⁰Dept. of Biomedical Imaging and Image-guided Therapy, Medical University of Vienna, Vienna, Austria, ¹¹Division of Neuroradiology and Musculoskeletal Radiology, Medical University of Vienna, Vienna, Austria, Vienna, Austria, ¹²Division of Nuclear Medicine, Medical University of Vienna, Vienna, Austria, ¹³Center for Neuropathology and Prion Research, LMU University Hospital, LMU Munich, Munich, Germany, ¹⁴German Cancer Consortium (DKTK), University Hospital, Partnersite LMU Munich, Munich, Germany, ¹⁵Bavarian Cancer Research Center (BZKF), Munich, Germany, ¹⁶Dept. of Neurology, LMU University Hospital, LMU Munich, Munich, Germany, ¹⁷Dept. of Neurosurgery, LMU University Hospital, LMU Munich, Munich, Germany, Munich, Germany, ¹⁸Dept. of Neurosurgery, Knappschaft University Hospital Bochum, Bochum, Germany, ¹⁹Dept. Radiation Oncology, LMU University Hospital, LMU Munich, Munich, Germany, ²⁰Institute of Neuroradiology, LMU University Hospital, LMU Munich, Munich, Germany, ²¹Dept. of Nuclear Medicine, University Hospital RWTH Aachen, Aachen, Germany, ²²Department of Radiology and Nuclear Medicine, Maastricht University Medical Center (MUMC+), Maastricht, Netherlands, ²³Center for Integrated Oncology Aachen Bonn Cologne Duesseldorf (CIO ABCD), , Germany

Background

O-(2-[¹⁸F]fluoroethyl)-L-tyrosine ([¹⁸F]FET) PET is predominantly applied for molecular imaging of diffuse gliomas. In contrast, data on the clinical utility of [¹⁸F]FET PET in circumscribed astrocytic gliomas (CAG) remain scarce.

Methods

We retrospectively identified adult CAG patients who underwent [¹⁸F]FET PET imaging (i) before diagnosis, (ii) at suspected relapse, or (iii) for response assessment at three institutions. Maximum and mean tumor-to-brain ratios (TBRmax, TBRmean) and metabolic tumor volumes were assessed according to the PET RANO 1.0 criteria. Diagnostic performance in differentiating treatment-related changes from tumor relapse was evaluated using ROC analysis and Fisher's exact test.

Results

We evaluated 79 [¹⁸F]FET PET scans of 42 patients, including nine (21%) with actionable molecular targets. 65% of CAG WHO grade 1 and 100% of CAG WHO grade 2 or 3 had measurable [¹⁸F]FET uptake according to



the PET RANO 1.0 criteria. In these patients, TBR values of CAG WHO grade 2 or 3 were significantly higher than in pilocytic astrocytomas ($P < 0.01$). There was no significant difference in TBR between CAG with or without actionable targets ($P > 0.05$). Following various treatments, response assessment according to the PET RANO 1.0 criteria differed from changes in MRI in 5 of 11 patients (45%). Treatment-related changes were confirmed neuropathologically or clinicoradiologically in 12 patients (43%). In CAG WHO grade 2 or 3, the accuracy of [^{18}F]FET PET to identify treatment-related changes was 82% using single PET scans and 100% using serial PET imaging ($P < 0.05$).

Conclusions

[^{18}F]FET PET can add valuable information for clinical management of patients with CAG.

Author disclosure: Maximilian J. Mair has received research funding from Bristol-Myers Squibb and travel support from Pierre Fabre. Hannah C. Puhr has received travel support from Eli Lilly, MSD, Novartis, Pfizer and Roche and lecture honoraria from Eli Lilly. Anna Sophie Berghoff has research support from Daiichi Sankyo, Roche and honoraria for lectures, consultation or advisory board participation from Roche Bristol-Meyers Squibb, Merck, Daiichi Sankyo, AstraZeneca, CeCaVa, Seagen, Alexion, Servier as well as travel support from Roche, Amgen and AbbVie. Georg Widhalm has received honoraria for advisory board participation from Servier. Franziska Eckert has received honoraria for lectures, consultation or advisory board participation from Dr. Sennewald medizintechnik and Servier. Gregor Kasprian has received honoraria for lectures from Bracco, and advisory board participation from Lilly. Louisa von Baumgarten has received honoraria for lectures, consultation or advisory board participation from Merck and Servier, and research funding from Novocure and Telix Pharmaceuticals. Niklas Thon has received honoraria for lectures, consultation or advisory board participation from Servier and Brainlab and research funding from Novocure. Felix M. Mottaghy is a medical advisor and consultant for Advanced Accelerator Applications (AAA) GmbH/Novartis, Telix Pharmaceuticals, and CURIUMTM, and has recently received institutional grants from NanoMab Technology Ltd., Radiopharm Ltd., Siemens Healthcare, and GE Precision Healthcare LLC. Philipp Lohmann has received honoraria for lectures from Blue Earth Diagnostics, and for advisory board participation from Servier. Karl-Josef Langen received honoraria from Telix Pharmaceuticals for consultancy services. Norbert Galldiks has received honoraria for lectures from Blue Earth Diagnostics, for advisory board participation from Telix Pharmaceuticals and Servier, and for consultancy services from Telix Pharmaceuticals. Nathalie L. Albert has received honoraria for lectures, consultation or advisory board participation from Advanced Accelerator Applications, Medsir, Novartis, Onclive, Servier and Telix Pharmaceuticals, and research funding from Novocure and Telix Pharmaceuticals. Matthias Preusser has received honoraria for lectures, consultation or advisory board participation from the following for-profit companies: Bayer, Bristol-Myers Squibb, Novartis, Gerson Lehrman Group (GLG), CMC Contrast, GlaxoSmithKline, Mundipharma, Roche, BMJ Journals, MedMedia, Astra Zeneca, AbbVie, Lilly, Medahead, Daiichi Sankyo, Sanofi, Merck Sharp & Dome, Tocagen, AdastrA, Gan & Lee Pharmaceuticals, Janssen, Servier, Miltenyi, Böhringer-Ingelheim, Telix, Medscape.



Abstract Number: 59

Abstract Title: Prognostic value of 18F-FET PET in patients with recurrent glioblastoma

Authors

Geens W¹, Buyck F¹, Menegatti M², Raes L³, Schwarze J⁴, Awada G⁴, Dirven I⁴, De Sutter S⁵, Bruneau M¹, Vandemeulebroucke J⁵, Everaert H³, Neyns B⁴, Duerinck J¹

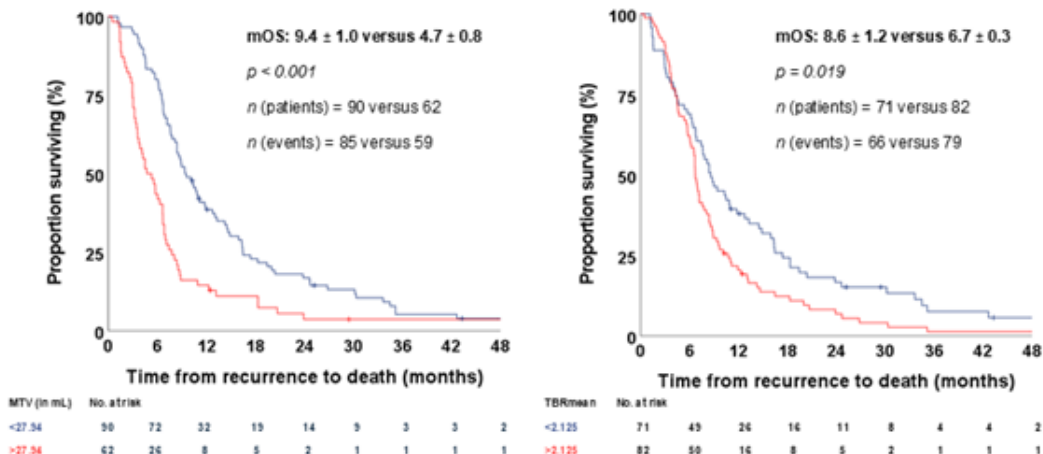
¹Department of Neurosurgery, UZ Brussel, Brussels, Belgium, ²Department of Neurosurgery, Azienda Ospedaliera Santa Maria di Terni, Terni, Italy, ³Department of Nuclear Medicine, UZ Brussel, Brussels, Belgium, ⁴Department of Medical Oncology, UZ Brussel, Brussels, Belgium, ⁵Department of Electronics and Informatics (ETRO), Vrije Universiteit Brussel, Brussels, Belgium

Determining prognosis in patients with recurrent glioblastoma (rGBM) remains challenging. This study aimed to evaluate the prognostic value of static O-(2-18F-fluoroethyl)-L-tyrosine (18F-FET) PET parameters in patients with rGBM.

153 patients treated in the context of three institutional clinical trials investigating the effectiveness of vascular endothelial growth factor (VEGF) inhibition, immune checkpoint inhibition, or a combination of both in rGBM were retrospectively evaluated. Patients with baseline 18F-FET PET were included in the analysis and stratified according to study therapy. The prognostic value of static parameters was evaluated using univariate Kaplan-Meier survival analysis and multivariate Cox regression analysis (including Karnofsky Performance Scale, gender, age, and corticosteroid use at baseline). Threshold values were identified using ROC analysis.

Both univariate and multivariate analysis revealed that patients with larger baseline Metabolic Tumor Volume (MTV) and higher mean Tumor-to-Brain Ratio (TBRmean) had increased risk of death independent of treatment at any given timepoint (for MTV per 10 mL: HR 1.07, [95% CI 1.01 - 1.12], p=0.016; for TBRmean: HR=1.71 [95% CI 1.03-2.83], p=0.038). ROC analysis showed that an MTV and TBRmean of more than 27.94mL and 2.125, respectively, are associated with significantly worse survival.

Our results suggest that pre-treatment MTV and TBRmean have a significant prognostic value in this patient group independent of treatment and could be useful to stratify and select patients for future clinical trials.





Abstract Number: 60

Abstract Title: The many faces of primary CNS T cell lymphoma: a multicentric, retrospective study of histopathologic, molecular and neuroimaging features

Authors:

Müller K¹, Forbrig R², Reis J², Gakis G¹, Englert B³, Karschnia P⁴, Kaulen L⁵, Hinz F⁶, Traub B⁵, Ehret F⁷, Connor E⁸, Martinez-Lage M⁸, Stöcklein V⁹, Dreyling M¹⁰, Rudelius M¹¹, Albert N¹², Straube A¹, Schöberl F¹, Harter P³, Dietrich J¹³, von Baumgarten L^{1,9}

¹Department of Neurology, University Hospital Of Munich, LMU, Munich, Germany, ²Department of Neuroradiology, University Hospital Of Munich, LMU, Munich, Germany, ³Center for Neuropathology and Prion Research, University Hospital of Munich, LMU, Munich, Germany, ⁴Department of Neurosurgery, University Hospital of the Friedrich-Alexander-University, Erlangen-Nuremberg, Erlangen-Nuremberg, Germany, ⁵Department of Neurology, University Hospital Heidelberg, Heidelberg, Germany, ⁶Department of Neuropathology, Institute of Pathology, University Hospital Heidelberg, Heidelberg, Germany, ⁷Department of Radiation Oncology, Massachusetts General Hospital, Boston, USA, ⁸Department of Pathology, Massachusetts General Hospital, Boston, USA, ⁹Department of Neurosurgery, University Hospital of Munich, LMU Munich, Munich, Germany, ¹⁰Department of Medicine III, University Hospital of Munich, LMU Munich, Munich, Germany, ¹¹Institute of Pathology, Ludwig-Maximilians-University of Munich, Munich, Germany, ¹²Department of Nuclear Medicine, University Hospital of Munich, LMU Munich, Munich, Germany, ¹³Department of Neurology, Massachusetts General Hospital, Boston, USA

Background

Primary CNS T cell lymphoma (PCNSTL) is an extremely rare and aggressive form of non-Hodgkin lymphoma. Diagnosis is often challenging due to its nonspecific presentation. In our study we aimed to analyse the clinical, histopathologic, molecular, and imaging characteristics of PCNSTL.

Methods

Histologically confirmed PCNSTL cases without evidence of systemic disease were identified at three centres (University Hospital of Munich, Heidelberg University, Massachusetts General Hospital). Retrospective data including histopathology, immunophenotyping, multimodal MRI, and PET imaging were analysed.

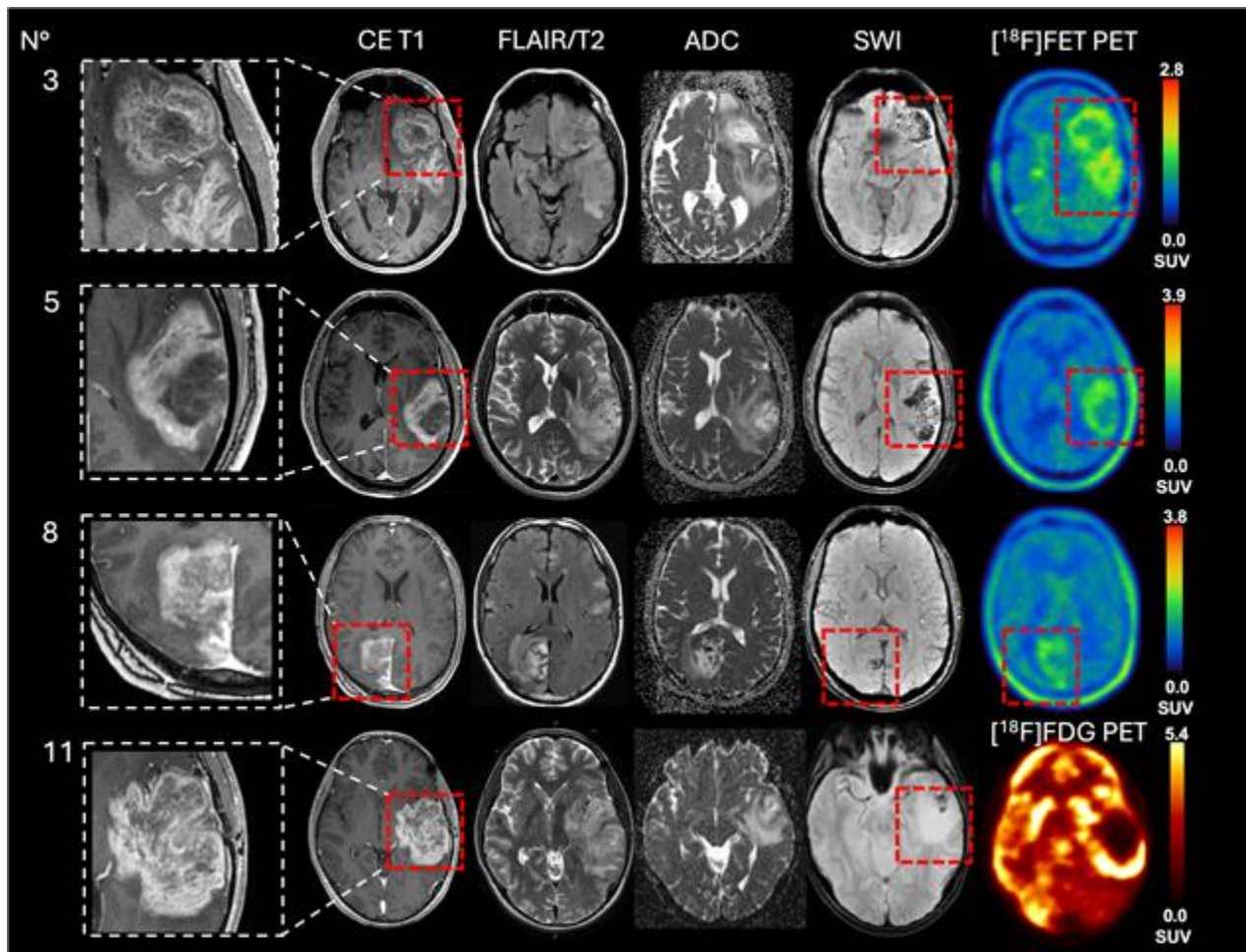
Results

We evaluated 16 immunocompetent patients (11 male) with a median age of 50 years (19-76) and median Karnofsky performance status of 70% (20-100). T-cell clonality was confirmed in 43.75% of cases by T-cell receptor gene rearrangement testing. Next generation sequencing revealed only mutational variants of uncertain significance in 18.75% (BCOR, MED12, MET genes). MRI at primary diagnosis showed supratentorial, highly contrast-enhancing lesions in 87.5% with frequent multifocality (37.5%). Compared to the aggressive contrast enhancement on MRI, [¹⁸F]FET-PET imaging showed only low to moderate tracer uptake in 3/4 available studies (18.75%). Median progression-free survival was five months, and median overall survival was 96.5 months. There was more favourable overall survival in the subgroup treated with MTX-based chemotherapy combined with autologous stem cell transplant (ASCT, p<0.0275). In one ALK1-positive PCNSTL persistent complete remission was achieved after treatment with Lorlatinib.


Conclusion

Although PCNSTL is exceptionally rare, we identified neuroimaging and histopathologic patterns, which may assist in identifying future PCNSTL cases. Best therapeutic response was observed after MTX-based

chemotherapy combined with ASCT. We report on the first ALK1-positive PCNSTL case with persistent complete remission after targeted therapy with Lorlatinib.



Author disclosure: Katharina J. Müller: received grant support by the Friedrich-Baur-Stiftung and DFG (German Research Society). Albert N has received honoraria for lectures, consultation or advisory board participation from Novartis / Advanced Accelerator Applications, Telix Pharmaceuticals, Servier and OncLive and research funding from Novocure and Telix Pharmaceuticals.



Abstract Number: 61

Abstract Title: Rhenium Obisbameda (Reyobiq) in Leptomeningeal Metastases

Authors:

Brenner A¹, Youssef M, DAmico R, Kumthekar P, Galvan E, Ong S, Floyd J, Bao A, Phillips W, Michalek J

¹Mays Cancer Center at UT Health San Antonio

BACKGROUND

Rhenium (¹⁸⁶Re) obisbameda (¹⁸⁶RNL, REYOBIQ) is BMEDA-chelated ¹⁸⁶Re encapsulated in liposomal nanoparticles. Leptomeningeal metastasis (LM) is a devastating cancer of the CSF and membranes surrounding the brain and spinal cord. Median overall survival is 2-6 months with treatment and 4-6 weeks without treatment. Preclinical studies have shown excellent ¹⁸⁶RNL tolerance by direct intraventricular injection in rodents with NOAEL of 1mCi and absorbed doses over 1000Gy.

METHODS

ReSPECT-LM is a multi-center dose-escalation Phase 1 clinical trial to evaluate the safety and tolerability of a single dose of ¹⁸⁶RNL given by the intraventricular route for LM.

RESULTS

36 patients were screened for enrollment in study cohorts 1-6. Doses ranged from 6.6mCi in cohort 1 through 75mCi in cohort 6. No dose limiting toxicity (DLT) was observed in cohorts 1-4, with 1 DLT in each cohort 5 and 6 of grade 4 thrombocytopenia. A dose dependent increase was observed in the absorbed dose to the cranial and spinal subarachnoid space reaching 253Gy in cohort 5. Response data was available for 16 patients as of the data cutoff with 5 of those (31%) showing a partial response. An additional 7 patients showed stable disease through day 112 for a Clinical Benefit Rate (CR+PR+SD) of 75%. Additionally, a clinical response with evident decrease in disease symptoms was noted in 2 of 14 evaluable patients (14%), and 10 showing stable symptoms through day 112 for a benefit rate of (86%). RNA sequencing of LM cells showed early induction of apoptosis, with an innate immune response followed by increase T cells and an adaptive immune response by day 28.

CONCLUSIONS

¹⁸⁶RNL shows excellent safety and promising activity for LM. The recommended phase 2 single dose is 44mCi. A multidose study is planned for Q1 2025 as well as exploration of immunotherapy combinations.

Author disclosure: A Brenner, A Bao, W Phillips are consultants for Plus Therapeutics.