

Paraneoplastic Syndromes, Autoimmune Encephalitis and Sensorineural Illness: A Review of a Potential Tool to Evaluate the Efficiency of the Anthroposophic Therapies

Maurício Martins Baldissin^{1,2}, Edna Marina de Souza³, Edmir A. Lourenço¹
¹Surgery Department, Jundiaí Medical School, Jundiaí, Brazil
²Neurodiagnosis and Neurotherapy Clinic, Jundiaí, Brazil
³Medical Physics Division, Biomedical Engineering Center, UNICAMP, Campinas, Brazil

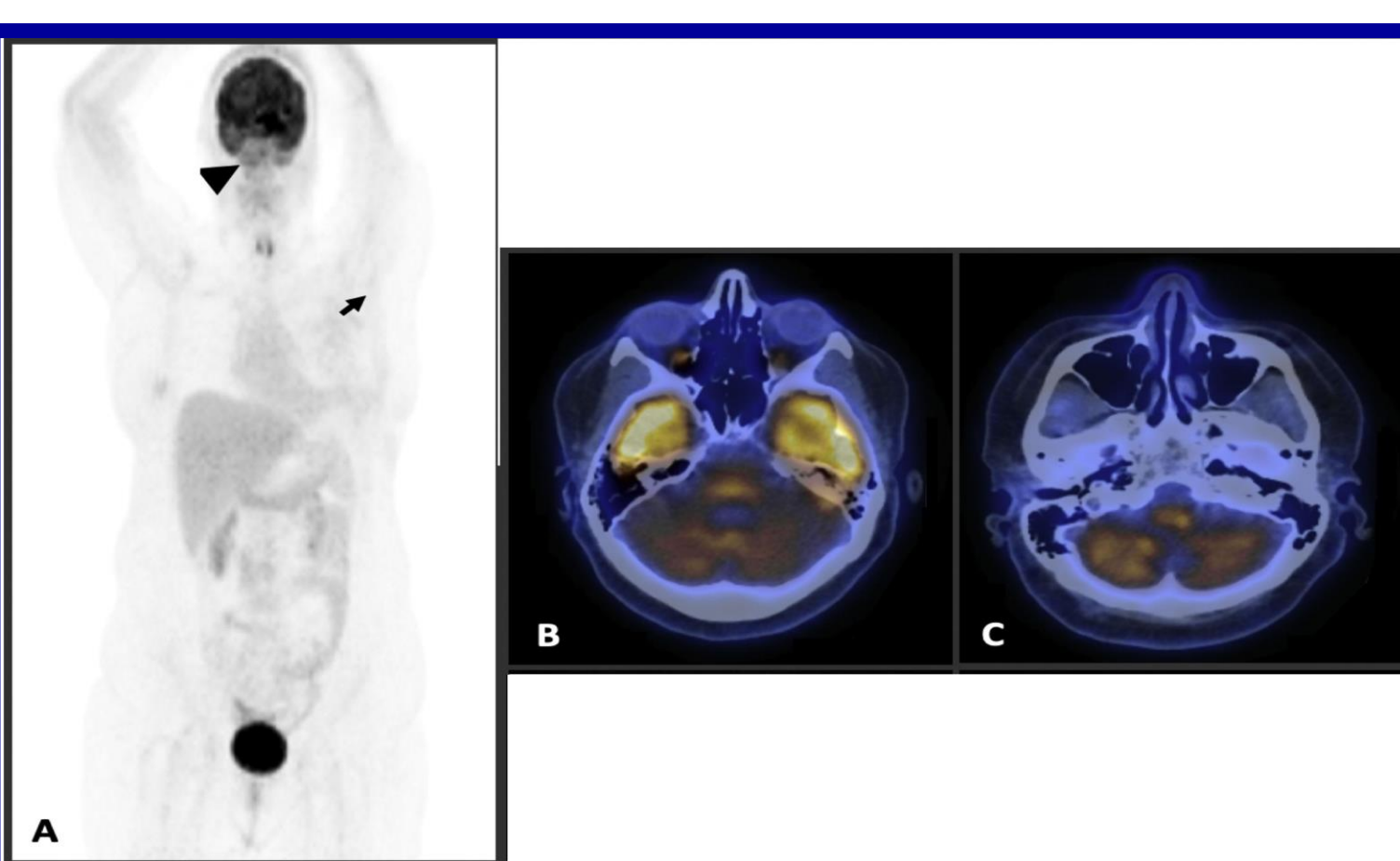
cl.neuro@terra.com.br

Background and Question

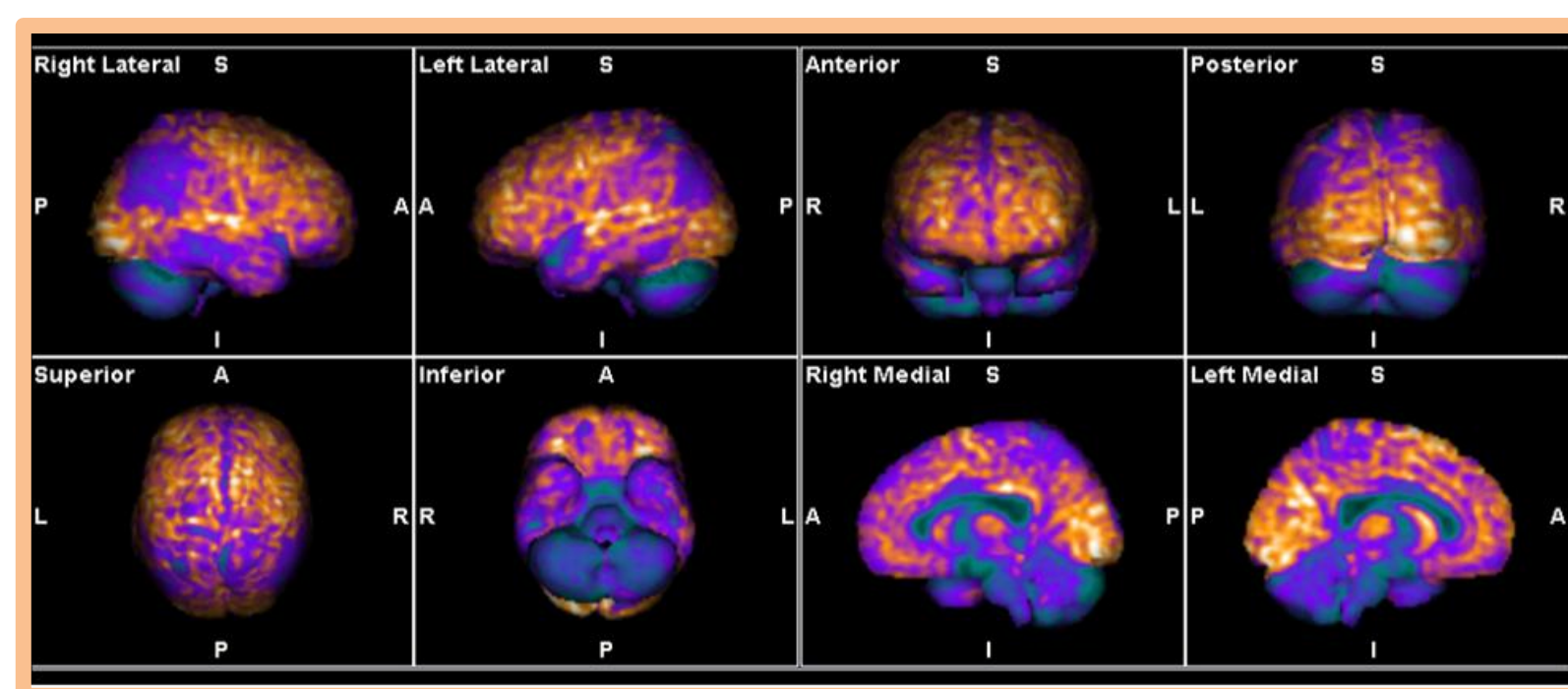
In the view of Rudolf Steiner, in severe cases of encephalitis, the pathological process leads to untying of the subtle bodies, as mentioned, “pushing the astral body through”. Each time the subject forth the efforts and succeeds, there is an aware afterwards of an emptiness behind the place where the astral body has been pushing through. This emptiness conscience come from the scape of the Self Organization [1]. The emptiness represents the susceptibility of the Self-Organization, reflecting in the metabolic, rhythmic, and sensorial systems, which can be mapped using auxiliary tools, as such as the brain FDG-PET/CT images, which can display the immune metabolic alterations in these conditions. In this context, this research summarizes a systematic review of the role of the brain FDG-PET/CT images [2] to describe the metabolic manifestations related to Autoimmune Encephalitis (AE) and Paraneoplastic Syndromes (PNS), as well as to evaluate the effects of the anthroposophic therapies on these patients [3].

Results

From 2,349 articles found, 56 satisfied the inclusion criteria (more than four subjects studied). For patients with AE, it was observed that specific manifestations of the brain metabolism maybe related with a specific type of antibody, according to the antibodies panel (A) (e.g., patients with anti-NMDA antibodies tend to manifest temporal hypermetabolism and occipital hypometabolism; in case of VGKC antibodies, a cortical diffuse hypometabolism has been observed); patients with PNS may showed different brain metabolic activity patterns, depending on the kind of primary tumor. Given the nature of the brain FDG-PET/CT images, the method has showed potential to follow-up patients submitted to anthroposophic therapies, which change the representation of the disease in the subtle bodies, consequently leading to changes in the brain metabolism (B). It was verified in a patient with AE and epileptic seizures, for which the treatment was based on the anthroposophic medicines [3].

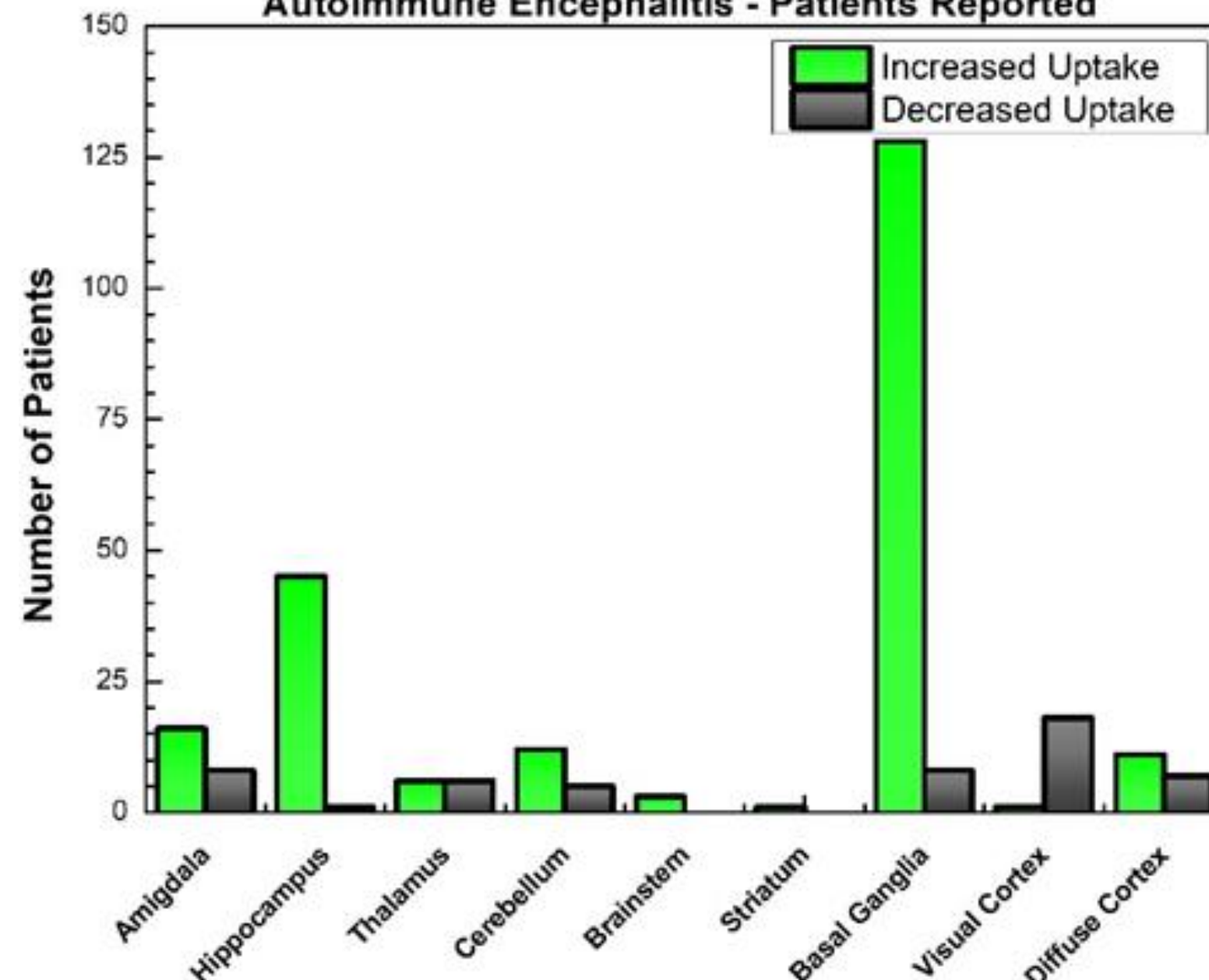


Examples of ¹⁸F-FDG PET/CT images of a patient with PNS, showing cerebellar hypometabolism.

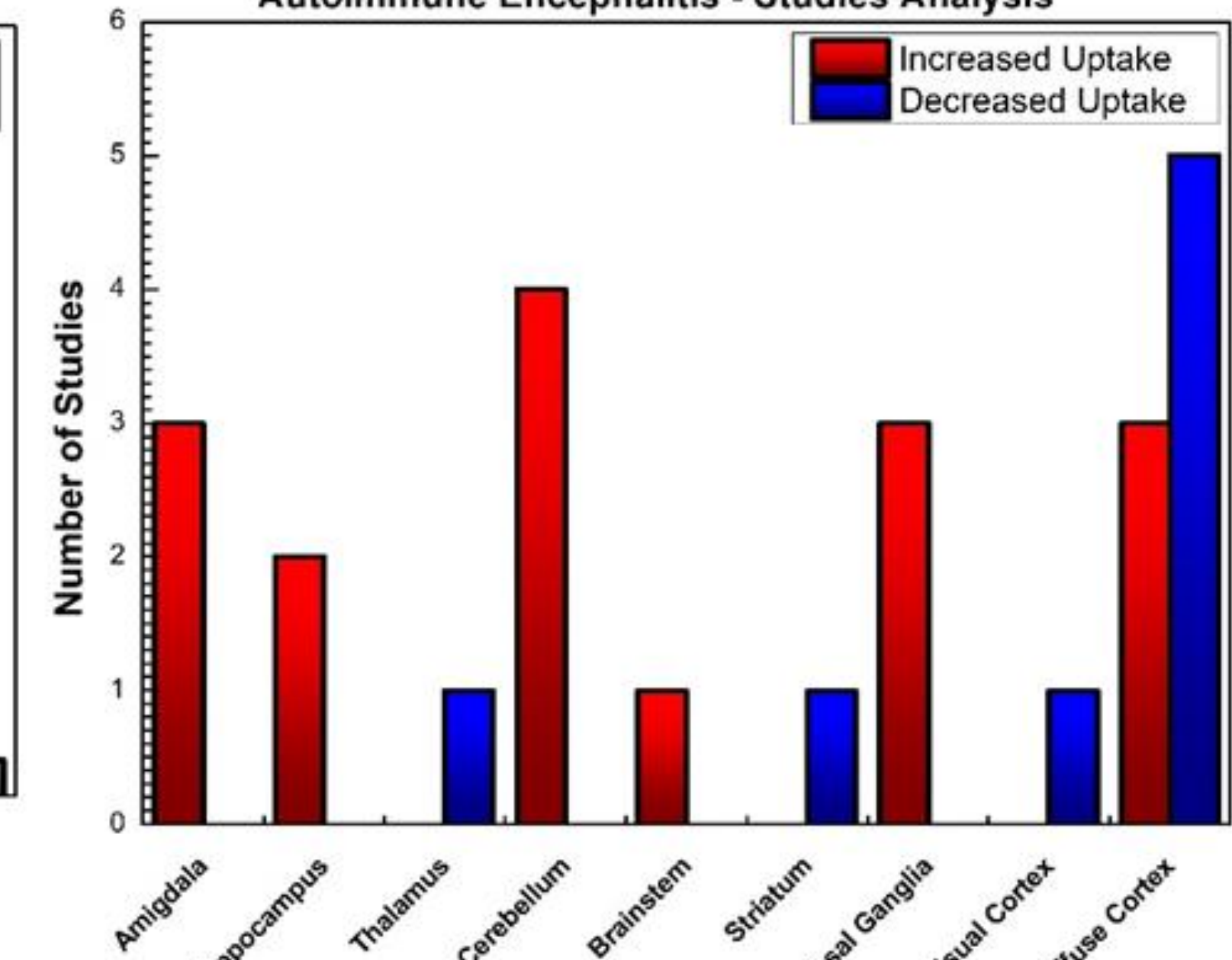


FDG PET/CT images of a patient with AE and the positive NMDA antibodies. The 3D reconstructions of the ¹⁸F-FDG PET/CT show a hypometabolism in both parietal lobes and cerebellum.

PET Findings of Brain Regions Metabolism of Patients with Autoimmune Encephalitis - Patients Reported



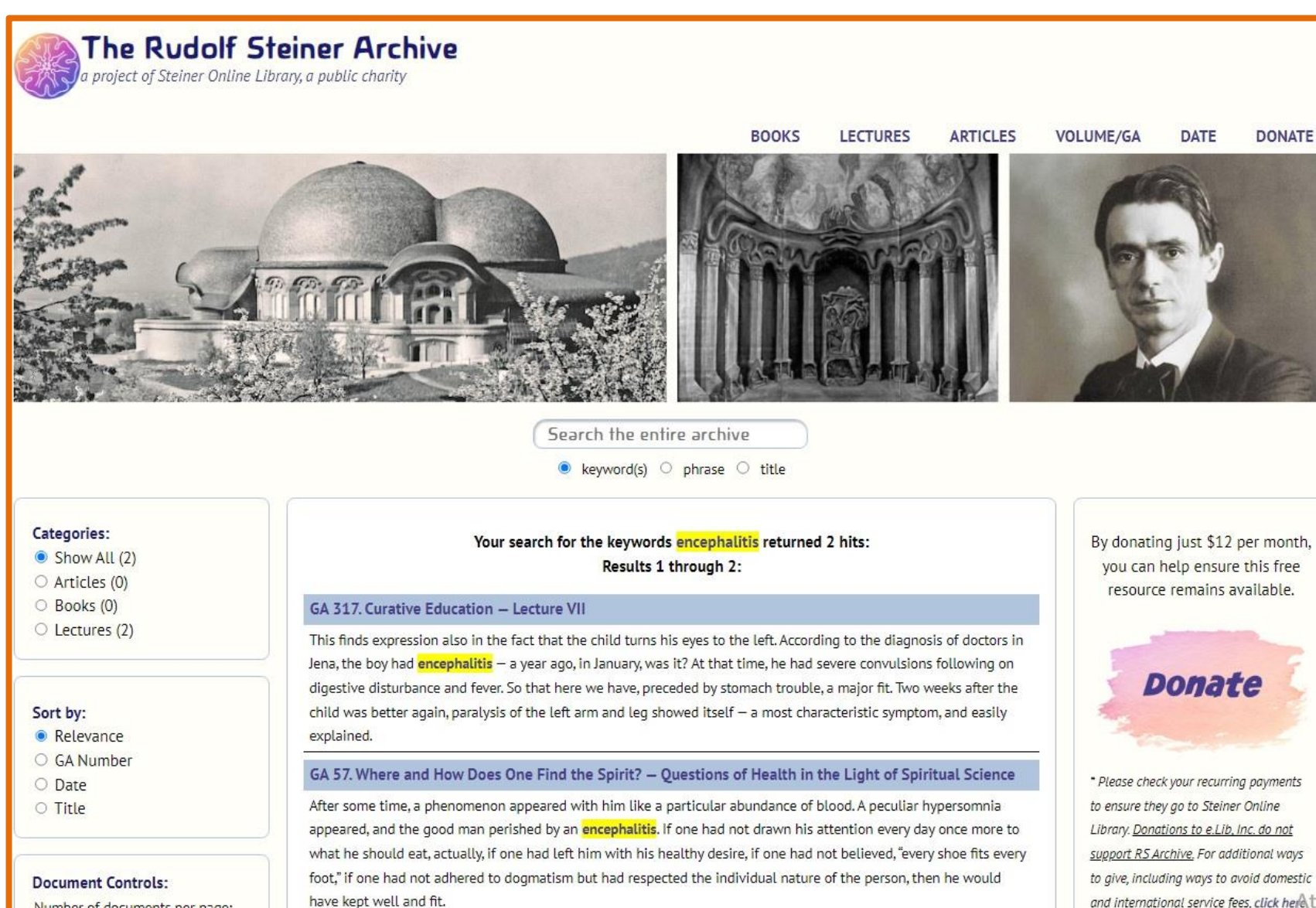
PET Findings of Brain Regions Metabolism of Patients with Autoimmune Encephalitis - Studies Analysis



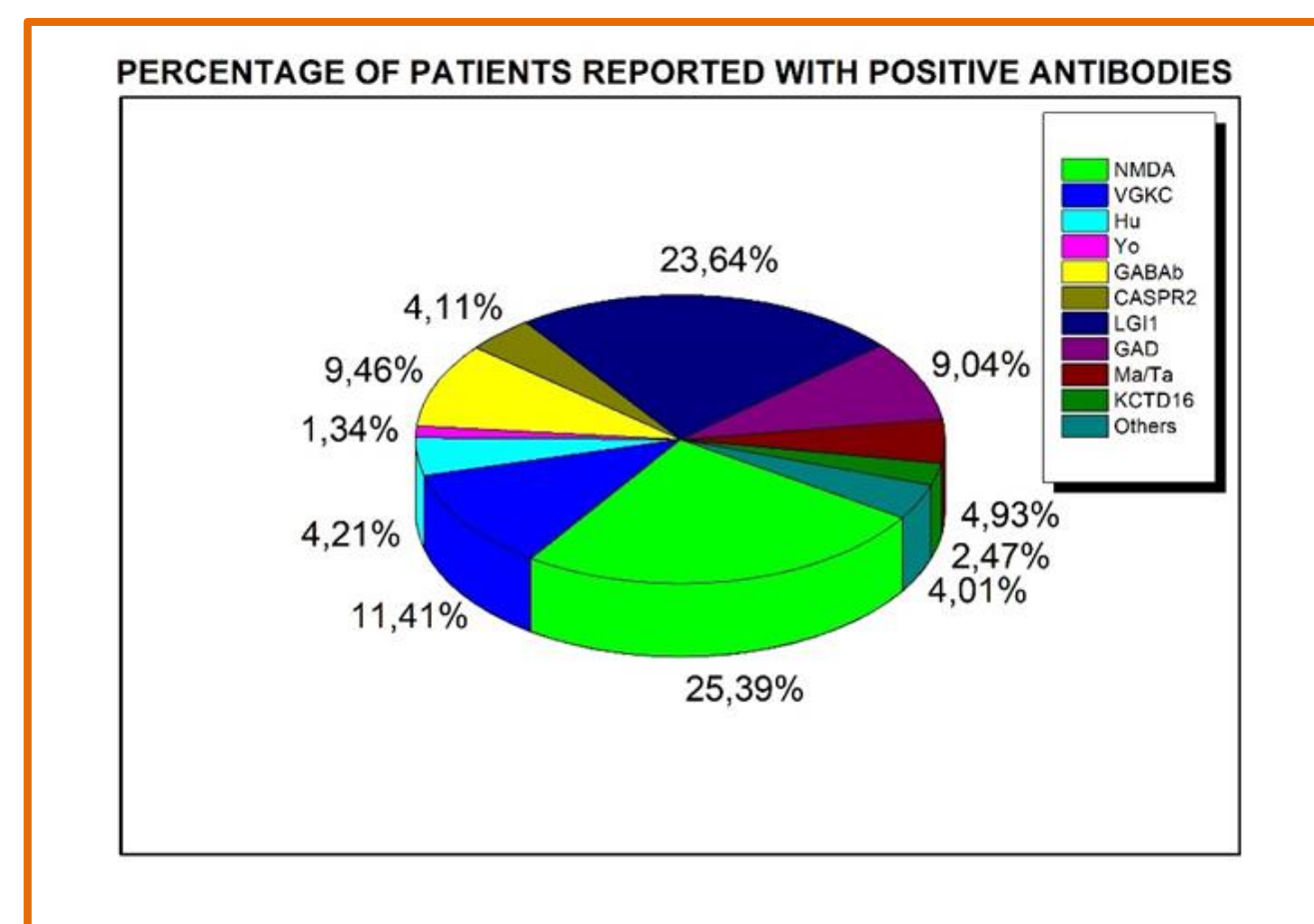
(A)

(B)

Brain regions with hypermetabolism and hypometabolism on FDG-PET. Number of PET findings for brain areas of patients with AE for studies which considered individual subjects' analysis (A) and group analysis (B).



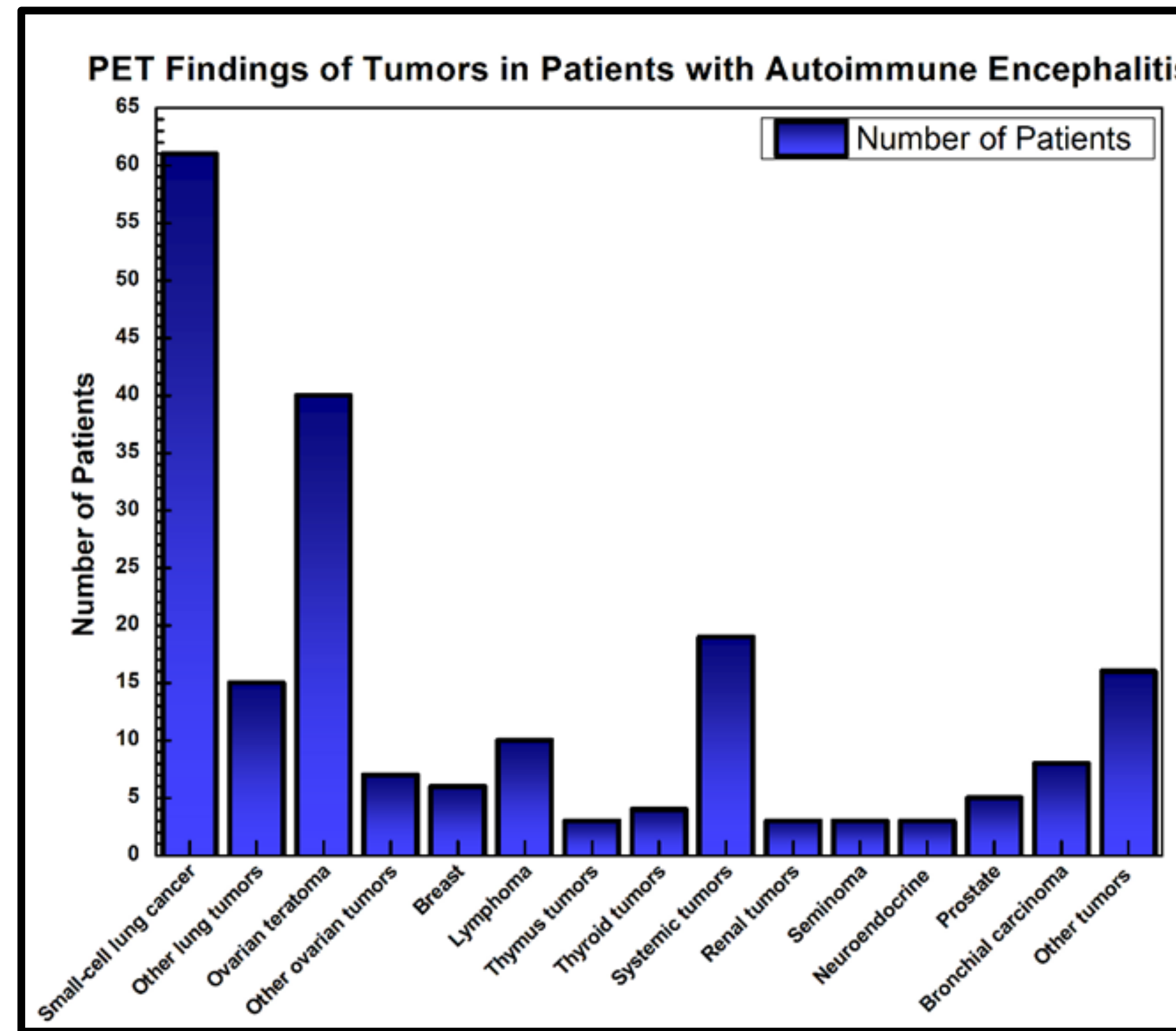
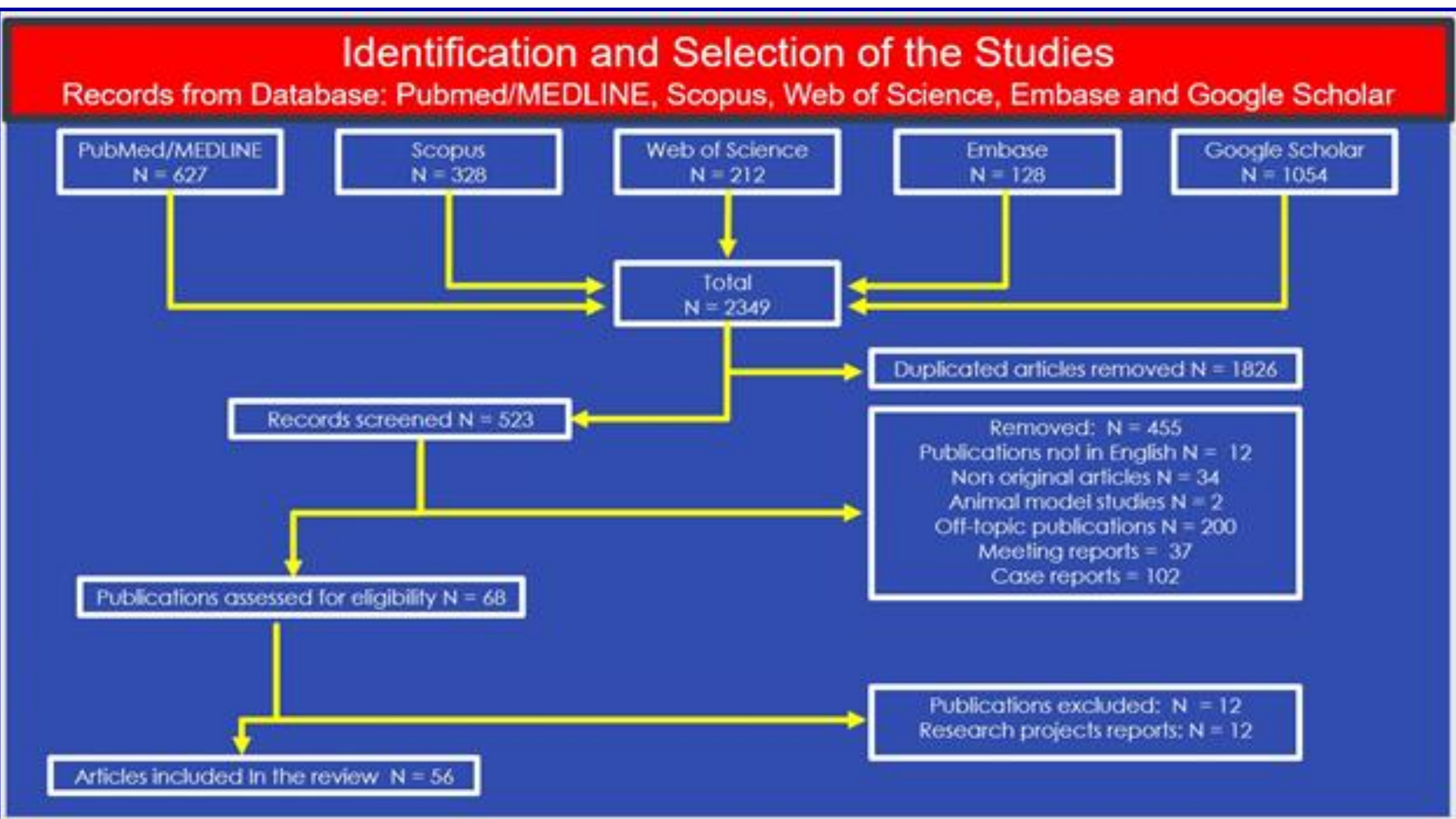
Encephalitis as cited by Rudolf Steiner [1].



Percentage of patients which present positive antibodies and brain FDG-PET alterations. In this Figure we included only patients with FDG-PET alterations and positive antibodies.

Materials and Methods

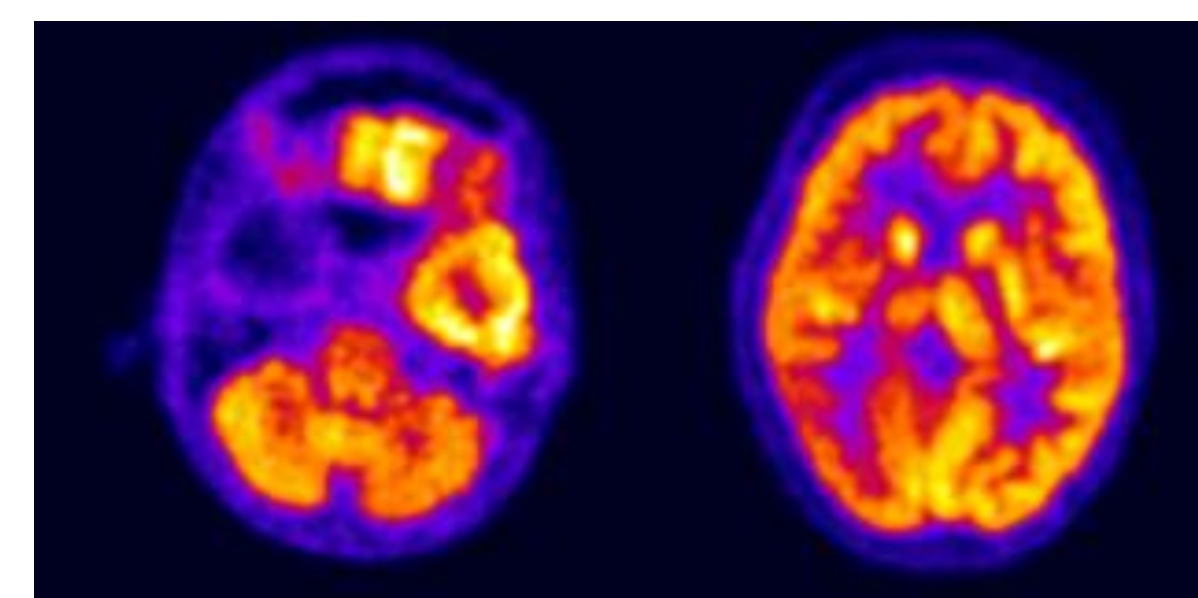
An organized literature search was conducted in the web, using the words “autoimmune encephalitis”, “¹⁸F-FDG PET/CT”, “brain inflammation”, terms related to antibodies description, and “encephalitis in the Rudolf Steiner Archives”. The search and analysis of publications were performed according to the PRISMA statement, and the quality of the methodological approaches of the articles was assessed based on the Quality Assessment of Diagnostic Accuracy Studies version 2 (QUADAS-2). The findings of the systematic review [2] have been correlated with a case of a patient with AE treated with anthroposophic therapies [3].



Distribution of the main tumors found in the literature using PET in patients with symptoms of AE.

Anthroposophic Therapies Applied
Medicines
<i>Hellborus D6 (oral and injectable)</i>
<i>Cuprum Aceticum D4 (injectable)</i>
<i>Zincum Valeriana D6 (injectable)</i>
<i>Bryophyllum Argentum Cultum D5 (injectable)</i>
<i>Calycinum D5 (injectable)</i>
<i>Calcarea Carbonica D6 (injectable)</i>
<i>Rhus D4 + Hypericum D5 + Bryonia D5 (injectable)</i>
<i>Chelidonium D5 + Cardum D5 (injectable)</i>
<i>Viscum P (Iscador) (injectable)</i>

PET images of the patient after the hippocampectomy, with hypometabolism in the right temporal lobe.



PET images of the patient after the hippocampectomy, with hypometabolism in the right temporal lobe.

Discussion and Conclusion

As well as applied to study of the brain metabolic changes in different phases and types of AE and PNS, the brain FDG-PET/CT images is a potential technique to evaluate the effects of the anthroposophic therapies on these conditions. It has been shown as an important tool to measure the anti-inflammatory and immunotherapy activities of the viscum album, administrated stand-alone or combined with other medicines.

References

- [1] Steiner R. Curative Education, GA 317, Lecture VII, 2 July 1924, Dornach. <https://rsarchive.org/Lectures/GA317/English/RSP1972/19240702p01.html>
- [2] Baldissin MM, de Souza EM et. al. FDG-PET in Patients with Autoimmune Encephalitis: A Review of Findings and New Perspectives. Clinical Translational Imaging, 2023. DOI: 10.1007/s40336-023-00581-5 <https://link.springer.com/article/10.1007/s40336-023-00581-5> (Ph.D. research).
- [3] Baldissin MM, de Souza EM. Limbic encephalitis and refractory mesial temporal lobe epilepsy: a single case study of neurosurgery and medical anthroposophic therapies. Der Merkurstab., v.76, p. 41-45, 2023. <https://doi.org/10.14271/DMS-21591-DE>